

Essentials

for students



PLASTIC SURGERY
EDUCATIONAL FOUNDATION

plastic surgery

The American Society of Plastic Surgeons® (ASPS®) is the largest organization of board-certified plastic surgeons in the world. With over 6,000 members, the society is recognized as a leading authority and information source on cosmetic and reconstructive plastic surgery. ASPS comprises 94 percent of all board-certified plastic surgeons in the United States. Founded in 1931, the society represents physicians certified by The American Board of Plastic Surgery, Inc.® or The Royal College of Physicians and Surgeons of Canada.

ASPS is recognized as the voice of plastic surgery by the public, organized medicine, industry, and government and works to position its members for success in a highly competitive environment through educational forums and the development of guidelines and products to enhance the profession.

Essentials

for students



AMERICAN SOCIETY OF
PLASTIC SURGEONS

plastic surgery



AMERICAN SOCIETY OF
PLASTIC SURGEONS



PLASTIC SURGERY
EDUCATIONAL FOUNDATION

YOUNG PLASTIC SURGEONS COMMITTEE

Adam Lowenstein, Chair
David H. Song, MD, Vice Chair

Seventh Edition 2007

Essentials for Students Workgroup
David H. Song, MD
Ginard Henry, MD
Russell R. Reid, MD, PhD
Liza C. Wu, MD
Garrett Wirth, MD
Amir H. Dorafshar, MBChB

UNDERGRADUATE EDUCATION COMMITTEE OF THE PLASTIC SURGERY EDUCATIONAL FOUNDATION

First Edition 1979

Ruedi P. Gingrass, MD, Chairman
Martin C. Robson, MD
Lewis W. Thompson, MD
John E. Woods, MD
Elvin G. Zook, MD

Copyright © 2007 by the

Plastic Surgery Educational Foundation
444 East Algonquin Road
Arlington Heights, IL 60005

14th Printing 2007

All rights reserved.

Printed in the United States of America

INTRODUCTION

This book has been written primarily for medical students, with constant attention to the thought, "Is this something a student should know when he or she finishes medical school?" It is not designed to be a comprehensive text, but rather an outline that can be read in the limited time available in a burgeoning curriculum. It is designed to be read from beginning to end.

Plastic surgery had its beginning thousands of years ago, when clever surgeons in India reconstructed the nose by transferring a flap of cheek and then forehead skin. It is a modern field, stimulated by the challenging reconstructive problems of the unfortunate victims of the World Wars. The advent of the operating microscope has thrust the plastic surgeon of today into the forefront of advances in small vessel and nerve repair, culminating in the successful replantation of amputated parts as small as distal fingers. Further, these techniques have been utilized to perform the first composite tissue transplantations of both hands and partial faces. The field is broad and varied and this book covers the many areas of involvement and training of today's plastic surgeons.

The American Society of Plastic Surgeons is proud to provide complimentary copies of the Plastic Surgery *Essentials for Students* handbook to all third year medical students in the United States and Canada.

Continually updated information about various procedures in plastic surgery and other medical information of use to medical students and other physicians can be found at the ASPS/PSEF website at www.plasticsurgery.org.

TABLE OF CONTENTS

| | |
|---|-----|
| Preface: | |
| A Career in Plastic Surgery | i |
| Chapter 1: Wounds | 1 |
| Chapter 2: Grafts and Flaps | 10 |
| Chapter 3: Skin and Subcutaneous Lesions | 18 |
| Chapter 4: Head and Neck | 32 |
| Chapter 5: Breast, Trunk and External Genitalia | 53 |
| Chapter 6: Upper Extremity | 68 |
| Chapter 7: Lower Extremity | 81 |
| Chapter 8: Thermal Injuries | 89 |
| Chapter 9: Aesthetic Surgery | 107 |
| Chapter 10: Body Contouring | 113 |

PREFACE

A CAREER IN PLASTIC SURGERY

Originally derived from the Greek “plastikos” meaning to mold and reshape, plastic surgery is a specialty which adapts surgical principles and thought processes to the unique needs of each individual patient by remodeling, reshaping and manipulating bone, cartilage and all soft tissues. Not concerned with a given organ system, region of the body, or age group, it is best described as a specialty devoted to the solution of difficult wound healing and surgical problems, having as its ultimate goal the restoration or creation of the best function, form and structure of the body with a superior aesthetic appearance ultimately enhancing a patient’s quality of life.

Plastic surgeons emphasize the importance of treating the patient as a whole. Whether reconstructing patients with injuries, disfigurements or scarring, or performing cosmetic procedures to recontour facial and body features not pleasing to the patient, plastic surgeons are concerned with the effect of the outcome on the entire patient. Not necessarily concerned with a set and limited repertoire of surgical procedures, plastic surgery is more a point of view with the ultimate goal of solving problems and thus, exposure to a wide variety of surgical problems and disciplines enhance the ability of the plastic surgeon to care for all patients.

The challenge of plastic surgery then is the wedding of the surgeon’s judgment and problem solving abilities to surgical technique at any given moment. Because of this approach, the plastic surgeon often acts as a “last resort” surgical consultant to surgeons and physicians in the treatment of many wound problems and is often called “the surgeon’s surgeon.”

Plastic surgery not only restores body function, but helps to renew or improve a patient’s body image and sense of self-esteem. Along with psychiatrists, plastic surgeons are especially equipped to handle the patient’s problem of body image and to help the patient deal with either real or perceived problems.

Consistent with these far reaching goals, the scope of the operations performed by plastic surgeons is extremely broad. As outlined by The American Board of Plastic Surgery, “the specialty of plastic surgery deals with the repair, replacement, and reconstruction of

physical defects of form or function involving the skin, musculoskeletal system, craniomaxillofacial structures, hand, extremities, breast and trunk, and external genitalia. It uses aesthetic surgical principles not only to improve undesirable qualities of normal structures, but in all reconstructive procedures as well.” Among the problems managed by plastic surgeons are congenital anomalies of the head and neck. Clefts of the lip and palate are the most common, but many other head and neck congenital deformities exist. In addition, the plastic surgeon treats injuries to the face, including fractures of the bone of the jaw and face.

Craniofacial surgery is a discipline developed to reposition and reshape the bones of the face and skull through inconspicuous incisions. Severe deformities of the cranium and face, which previously were uncorrectable or corrected with great difficulty, can now be better reconstructed employing these new techniques. Such deformities may result from a tumor resection, congenital defect, previous surgery, or previous injury. Treatment of tumors of the head and neck and reconstruction of these regions after the removal of these tumors is also within the scope of plastic surgery.

Another area of expertise for the plastic surgeon is hand surgery, including the management of acute hand injuries, the correction of hand deformities and reconstruction of the hand. Microvascular surgery, a technique that allows the surgeon to connect blood vessels of one millimeter or less in diameter, is a necessary skill in hand surgery for re-implanting amputated parts or in moving large pieces of tissue from one part of the body to another.

Defects of the body surface resulting from burns or from injuries, previous surgical treatment, or congenital deformities may also be treated by the plastic surgeon. One of the most common of such procedures is reconstruction of the breast following mastectomy. Breasts may also be reduced in size, increased in size, or changed in shape to improve the final aesthetic appearance. Operations of this type are sometimes cosmetic in purpose, but in cases where the patient has a significant asymmetry or surgical defect, the procedure serves important therapeutic purposes.

The most highly visible area of plastic surgery is aesthetic or cosmetic surgery. Cosmetic surgery includes facelifts, breast enlargements, nasal surgery, body sculpturing, and other similar operations to enhance one’s appearance.

The results of the plastic surgeon’s expertise and ability are highly visible, leading to a high degree of professional and personal satisfaction. The discipline requires meticulous attention to detail, sound judgment and technical expertise in performing the intricate and complex procedures associated with plastic surgery. In addition, plastic surgeons must possess a flexible approach that will enable them to work on a daily basis with a tremendous variety of surgical problems. Most importantly, the plastic surgeon must have creativity, curiosity, insight, and an understanding of human psychology.

Because of the breadth of the specialty and its ever changing content, opportunities for individuals with varied backgrounds is particularly important. Individuals with undergraduate majors ranging from art to engineering find their skills useful in various areas of plastic surgery. This need for a broad education continues into medical school.

Students should use elective time to acquire the broadest base of medical knowledge. Experience in surgery and psychiatry are of particular value. Clinical rotations in surgical specialties, such as neurosurgery, orthopaedics, otolaryngology, pediatric surgery, transplantation, or urology may prove more valuable than general surgery since most of the early residency experience will be in general surgery.

While there are several approved types of prerequisite surgical education, most candidates for the traditional plastic surgery residency programs have had from three to five years of training in general surgery after graduating from medical school. Applicants may also apply for a plastic surgery residency after completing a residency in otolaryngology, orthopaedics, neurosurgery, or urology or oral and maxillofacial surgery (the latter requiring two years of general surgery training in addition to an MD/DDS). Plastic surgery residency in the traditional format is generally for two or three years. Another residency model in plastic surgery is the Integrated Residency. Applicants apply to start immediately following graduation from medical school and will have either five or six years of training under the leadership of the program director of plastic surgery. Following residency training, many physicians spend an additional six to twelve months of fellowship training in a particular area of plastic surgery such as craniofacial surgery, aesthetic surgery, hand surgery, or microsurgery.

The American Board of Plastic Surgery (ABPS) issues a Booklet of Information each year which outlines the training and requirements for eligibility to take the examinations offered by the board. You may request information from ABPS at:

The American Board of Plastic Surgery, Inc.
Seven Penn Center, Suite 400
1635 Market Street
Philadelphia, PA 19103-2204
Phone: 215-587-9322
Fax: 215-587-9622
Email: info@abplsurg.org
Web: www.abplsurg.org

Traditionally, plastic surgeons have established their practices in large urban settings. However, there is an increasing need for more plastic surgeons in the smaller communities and rural areas of this country — many metropolitan areas with populations of 65,000 to 268,000 have no plastic surgeons, leaving a large number of areas needing plastic surgery expertise. There are approximately 6,000 board certified plastic surgeons in the United States; many of those currently certified by The American Board of Plastic Surgery received certification in the past ten years. Despite this recent rapid growth, there are opportunities for plastic surgeons in community and academic practice.

Plastic surgery is an old specialty with references that date back thousands of years. It has survived and flourished because it is a changing specialty built by imaginative, creative and innovative surgeons with a broad background and education.

The limit of the specialty is bound only by the imagination and expertise of those in its practice. The opportunities for the future are open to those who wish to be challenged.

ADDITIONAL RESOURCES ON THE SPECIALTY OF PLASTIC SURGERY

- I. American Society of Plastic Surgeons**
444 East Algonquin Road
Arlington Heights, IL 60005-4664
Phone: 847-228-9900
Fax: 847-228-9131
www.plasticsurgery.org
- II. Residency Review Committee for Plastic Surgery**
515 North State Street, Suite 2000
Chicago, IL 60610
Phone: 312-755-5000
Fax: 312-464-4098

CHAPTER 1

WOUNDS

A wound can be defined as a disruption of the normal anatomical relationships of tissues as a result of injury. The injury may be intentional such as a surgical incision or accidental following trauma. Immediately following wounding, the healing process begins.

I. STAGES OR PHASES OF WOUND HEALING

Regardless of type of wound healing, stages or phases are the same except that the time required for each stage depends on the type of healing.

- A. *Substrate* phase (inflammatory, lag or exudative stage or phase — days 1-4)
 1. Symptoms and signs of inflammation
 - a. Redness (*rubor*), heat (*calor*), swelling (*tumor*), pain (*tumor*), and loss of function
 2. Physiology of inflammation
 - a. Leukocyte margination, sticking, emigration through vessel walls
 - b. Venule dilation and lymphatic blockade
 - c. Neutrophil chemotaxis and phagocytosis
 3. Removal of clot, debris, bacteria, and other impediments of wound healing
 4. Lasts finite length of time (approximately four days) in primary intention healing
 5. Continues until wound is closed (unspecified time) in secondary and tertiary intention healing
- B. *Proliferative* phase (collagen and fibroblastic stage or phase — approximately days 4-42)
 1. Synthesis of collagen tissue from fibroblasts
 2. Increased rate of collagen synthesis for 42-60 days
 3. Rapid gain of tensile strength in the wound (Fig. 1-1)
- C. *Remodeling* phase (maturation stage or phase — from approximately three weeks onward)
 1. Maturation by intermolecular cross-linking of collagen leads to flattening of scar
 2. Requires approximately 9 months in an adult — longer in children
 3. Dynamic, ongoing

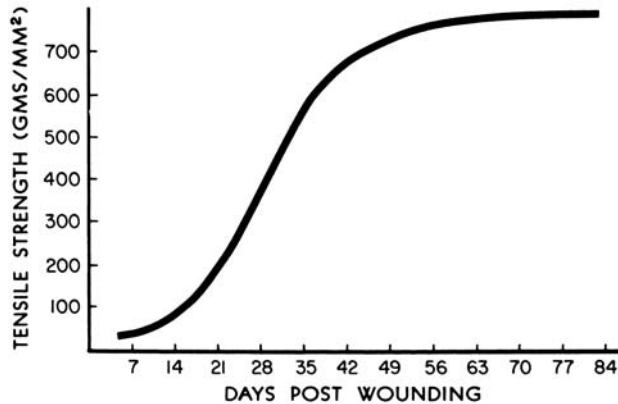


Fig. 1-1

II. WOUND CLOSURE

- A. *Primary* healing (by primary intention) — wound closure by direct approximation, pedicle flap or skin graft
 1. Debridement and irrigation minimize inflammation
 2. Dermis should be accurately approximated with sutures (see chart at end of chapter) or skin glue (i.e., Dermabond)
 3. Scar red, raised, pruritic, and angry-looking at peak of collagen synthesis
 4. Thinning, flattening and blanching of scar occurs over approximately 9 months in adults, as collagen maturation occurs (may take longer in children)
 5. Final result of scar depends largely on how the dermis was approximated
- B. *Spontaneous* healing (by secondary intention) — wound left open to heal spontaneously — maintained in inflammatory phase until wound closed
 1. Spontaneous wound closure depends on contraction and epithelialization
 2. Contraction results from centripetal force in wound margin probably provided by myofibroblasts
 3. Epithelialization proceeds from wound margins towards center at 1 mm/day

4. Although contraction (the process of contracting) is normal in wound healing, one must beware of contracture (an end result — may be caused by contraction of scar and is a pathological deformity)
 5. Secondary healing beneficial in some wounds, e.g. perineum, heavily contaminated wounds, scalp
- C. *Tertiary* healing (by tertiary intention) — delayed wound closure after several days
1. Distinguishing feature of this type of healing is the intentional interruption of healing begun as secondary intention
 2. Can occur any time after granulation tissue has formed in wound
 3. Delayed closure should be performed when wound is not infected (usually 10^5 or fewer bacteria/gram of tissue on quantitative culture except with beta-STREP)

III. FACTORS INFLUENCING WOUND HEALING

- A. Local factors most important because we can control them
 1. Tissue trauma — must be kept at a minimum
 2. Hematoma — associated with higher infection rate
 3. Blood supply
 4. Temperature
 5. Infection
 6. Technique and suture materials — only important when factors 1-5 have been controlled
- B. General factors — cannot be readily controlled by surgeon; systemic effects of steroids, nutrition, chemotherapy, chronic illness, etc., contribute to wound healing

IV. MANAGEMENT OF THE CLEAN WOUND

- A. Goal — obtain a closed wound as soon as possible to prevent infection, fibrosis and secondary deformity
- B. General principles
 1. Immunization — use American College of Surgeons Committee on Trauma recommendation for tetanus immunization
 2. If necessary, use pre-anesthetic medication to reduce anxiety

3. Local anesthesia — use Lidocaine with epinephrine unless contraindicated, e.g. tip of penis
4. Tourniquet to provide bloodless field in extremities
5. Cleansing of surrounding skin — do **NOT** use strong antiseptic in the wound itself
6. Debridement
 - a. Remove clot and debris, necrotic tissue
 - b. Copious irrigation good adjunct to sharp debridement
7. Closure — use atraumatic technique to approximate dermis. Consider undermining of wound edges to relieve tension
8. Dressing — must provide absorption, protection, immobilization, even compression, and be aesthetically acceptable

C. Types of wounds and their treatment

1. Abrasion — cleanse to remove foreign material
 - a. Consider scrub brush or dermabrasion to remove dirt buried in dermis to prevent traumatic tattoos (permanent discoloration due to buried dirt beneath new skin surface) — needs to be accomplished within 24 hours of injury
2. Contusion — consider need to evacuate hematoma if collection is present
 - a. Early — minimize by cooling with ice (24-48 hours)
 - b. Later — warmth to speed absorption of blood
3. Laceration — trim wound edges if necessary (ragged, contused) and suture
4. Avulsion
 - a. Partial (creates a flap) — revise and suture if viable
 - b. Total — do not replace totally avulsed tissue except as a skin graft after fat is removed
5. Puncture wound — evaluate underlying damage, possibly explore wound for foreign body, etc. Animal bites — debride and close primarily or leave open, depending upon anatomic location, time since bite, etc. Use antibiotics

D. Wounds of face

1. Important to use careful technique
 - a. Urgency should not override judgement
 - b. There is a longer “period of grace” during which the wound may be closed since blood supply to face is excellent
 - c. **Do not** forget about other possible injuries (chest, abdomen, extremities). **Very rare** for patient to die from facial lacerations alone
2. Facial lacerations of secondary importance to airway problems, hemorrhage or intracranial injury
3. Beware of overaggressive debridement of questionably viable tissue
4. Isolate cavities from each other by suturing linings, such as oral and nasal mucosa
5. Use anatomic landmarks to advantage, e.g. alignment of vermilion border, nostril sill, eyebrow, helical rim

E. Wounds of the upper extremity (*See Chapter 6*)

F. Special Wounds

1. Amputation of parts
 - a. Attempt replacement if within six hours of injury
 - b. Place amputated part in saline soaked gauze in a plastic bag and **the bag** in ice
2. Cheek injury — examine for parotid duct and/or facial nerve injury
3. Intraoral injuries — tongue, cheek, palate, and lip wounds require suturing
4. Eyelids — align grey line and close in layers — consider temporary tarsorrhaphy
5. Ear injuries
 - a. Hematoma — incision and drainage of hematoma and well-molded dressing to prevent cauliflower ear deformity
 - b. Through-and-through laceration requires 3 layer closure including cartilage
6. Animal bites — debridement, irrigation, antibiotics, and possible wound closure. Be particularly careful of cat bites which can infect with a very small puncture wound

V. MANAGEMENT OF THE “CONTAMINATED” WOUND

A. Guidelines for management of management of contaminated acute wounds

1. Majority of civilian traumatic wounds can be closed primarily after adequate debridement
 - a. Adequate debridement
 - i. Mechanical/sharp or chemical/enzymatic (eg, Collagenase, Panafil®)
 - ii. Irrigation — copious pulsatile lavage
 - b. Exceptions (may opt to leave wound open)
 - i. Heavy bacterial inoculum (human bites)
 - ii. Long time lapse since wounding (relative)
 - iii. Crushed or ischemic tissue — severe contused avulsion injury
 - iv. Sustained high-level steroid ingestion
2. Antibiotics — Systemic antibiotics are only of use if a therapeutic tissue level can be reached within four hours of wounding or debridement
3. Wound closure
 - a. Buried sutures should be used to keep wound edge tension to a minimum; however, each suture is a foreign body which increases the chance of infection (use least number of sutures possible to bring wound together without tension)
 - b. Skin sutures of monofilament material are less apt to become infected
 - c. Porous tape closure may be used for some wounds
4. Follow up — contaminated traumatic wounds should be checked for infection within 48 hours after closure
5. If doubt exists, it is always safer to delay closure (revision can be done later)

B. Guidelines for management of contaminated **chronic** wounds

1. Examples — wounds greater than 24 hours old
 - a. Common ingredient — granulation tissue
2. Debridement as important as in an acute wound
 - a. Excision (scalpel, scissors)
 - b. Frequent dressing changes
 - c. Enzymatic — seldom indicated

3. Systemic antibiotics of little use
4. Topical antibacterial creams — silver sulfadiazine (Silvadene®) and mafenide acetate (Sulfamylon®)
 - a. Continual surface contact
 - b. Good penetrating ability
 - c. Decrease bacterial counts of wounds
5. Biological dressings (allograft, xenograft, some synthetic dressings) debride wound, decrease pain.
6. Final closure
 - a. With a delayed flap, skin graft or flap
 - b. Convert the chronic contaminated wound bacteriologically to an acute clean wound by decreasing the bacterial count (debridement)

VI. WOUND DRESSINGS

- A. Protect the wound from trauma
- B. Provide environment for healing
- C. Antibacterial medications
 1. Bacitracin® and Neosporin®
 - a. Provide moist environment conducive to epithelialization
 2. Silver sulfadiazine (Silvadene®) and mafenide acetate (Sulfamylon®)
 - a. Useful for burns or other wounds with an eschar
 - b. Antibacterial activity penetrates eschar
- D. Splinting and casting
 1. For immobilization to promote healing
 2. Do not splint too long — may promote joint stiffness
- E. Pressure Dressings
 1. May be useful to prevent “dead space” (potential space in wound) or to prevent seroma/hematoma
 2. Do not compress flaps tightly
- F. Do not leave dressing on too long (<48 hours) before changing

| ETHICON® Synthetic Absorbable Sutures | | | | | |
|---|--------------------------------------|--|--|---|---|
| SUTURE & COMPOSITION | COLOR & TYPE | BSR | ABSORPTION RATE | MAIN BENEFIT | |
| Coated VICRYL® RAPIDE® (polyglactin 910) suture | Undyed Braided | 50% at 5 days 0% at 10 to 14 days | Essentially complete by 42 days | Skin and Mucosa: - Episiotomy repair - Lacerations under casts - Mucosa in oral cavity - Skin repairs where rapid absorption may be beneficial, excluding joints and high stress areas Soft Tissue Approximation: - Ligation - Skin Repairs - Bowel - Peritoneum - Uterus - Vaginal Cuff | Patient comfort No suture removal |
| MONOCRYL® (polylactone 25) suture | Undyed/Dyed (violet) Monofilament | Dyed: 60 to 70% at 7 days 30 to 40% at 14 days Undyed: 50 to 60% at 7 days 20 to 30% at 14 days | Essentially complete between 91 and 119 days | Soft Tissue Approximation: - Ligation - General Closure - Ophthalmic Surgery - Orthopaedic Surgery - Bowel Soft Tissue Approximation: - Fascia Closure - Orthopaedic Surgery - Blood Vessel Anatomoses - Pediatric Cardiovascular and Ophthalmic procedures - Patients with compromised wound healing conditions | Unprecedented monofilament pliability Smooth tissue passage |
| Coated VICRYL (polyglactin 910) suture | Undyed/Dyed (violet) Braided | 75% at 14 days 50% at 21 days† 40% at 21 days‡ | Essentially complete between 36 and 70 days | Soft Tissue Approximation: - Ligation - General Closure - Ophthalmic Surgery - Orthopaedic Surgery - Bowel Soft Tissue Approximation: - Fascia Closure - Orthopaedic Surgery - Blood Vessel Anatomoses - Pediatric Cardiovascular and Ophthalmic procedures - Patients with compromised wound healing conditions | Strength, preferred performance and handling Knot security |
| PDS® II (polydioxanone) suture | Undyed/Dyed (violet) Monofilament | 70% at 14 days 50% at 28 days 25% at 42 days | Essentially complete within 6 months | Soft Tissue Approximation: - Fascia Closure - Orthopaedic Surgery - Blood Vessel Anatomoses - Pediatric Cardiovascular and Ophthalmic procedures - Patients with compromised wound healing conditions | Longest-lasting absorbable monofilament wound support Outstanding pliability |

*Trademark

† Sizes 6/0 and larger

‡ Sizes 7/0 and larger

CHAPTER 1 — BIBLIOGRAPHY

WOUNDS

1. Alster, T.S., and West, T.B. Treatment of scars: a review. *Ann Plast Surg.* 1997; 39:418-32.
2. Eppley, B.L. Alloplastic Implantation. *Plast Reconstr Surg.* 1999; 104:1761-83.
3. Hunt, T.K., et al. Physiology of wound healing. *Adv Skin Wound Care.* 2000; 13 (suppl 6-11).
4. Klein, A.W. Collagen substitutes: bovine collagen. *Clin Plast Surg.* 2001; 28:53-62.
5. Lawrence, W.T. Physiology of the acute wound. *Clin Plast Surg.* 1998; 25: 321-40.
6. Mast, B.A., Dieselmann, R.F., Krummel, T.M., and Cohen, I.K. Scarless wound healing in the mammalian fetus. *Surg. Gynecol. Obstet.* 1992; 174:441.
7. Nwomeh, B.C., Yager, D.R., Cohen, K. Physiology of the chronic wound. *Clin Plast Surg.* 1998; 25:3.
8. Saltz, R. and Zamora, S. Tissue adhesives and applications in plastic and reconstructive surgery. *Aesthetic Plast Surg.* 1998; 22:439-43.
9. Stadleman, W.K., Digenis, A.G., and Tobin, G.R. Physiology and healing dynamics of chronic cutaneous wounds. *Am J Surg.* 1998; 176:26S-38S.
10. Terino, E.O. Alloderm acellular dermal graft: applications in aesthetic soft tissue augmentation. *Clin Plast Surg.* 2001; 28:83-99.
11. Witte, M.B., and Barbul, A. General principles of wound healing. *Surg Clin North Am.* 1997; 77:509-28.

CHAPTER 2

GRAFTS AND FLAPS

When a deformity needs to be reconstructed, either grafts or flaps can be employed to restore normal function and/or anatomy. For instance, when wounds cannot be closed primarily or allowed to heal by secondary intention, either grafts or flaps can be used to close an open wound.

Grafts — Grafts are harvested from a donor site and transferred to the recipient site without carrying its own blood supply. It relies on new blood vessels from the recipient site bed to be generated (angiogenesis).

I. SKIN GRAFTS

A. Thickness (Figure 2-1)

1. Full thickness — Full thickness skin grafts (FTSGs) consist of the entire epidermis and dermis
2. Split thickness — Split thickness skin grafts (STSGs) consist of the epidermis and varying degrees of dermis. They can be described as thin, intermediate, or thick
3. Harvested using a dermatome or freehand (Fig. 2-2)

B. Donor site

1. Full thickness — The full thickness skin graft leaves behind no epidermal elements in the donor site from which resurfacing can take place. Thus, the donor site of a FTSG must be closed. It must be taken from an area that has skin redundancy. It is usually harvested with a knife between the dermis and the subcutaneous fat
2. Split thickness — The split thickness skin graft leaves behind adnexal remnants such as hair follicles and sweat glands, foci from which epidermal cells can repopulate and resurface the donor site. It is usually harvested with either a special blade or dermatome that can be set to a desired thickness

C. Recipient site

1. Full thickness — Full thickness skin grafts are usually used to resurface smaller defects because they are limited in size. It is commonly used to resurface defects of the face. It provides a better color

consistency, texture, and undergoes less secondary contraction.

2. Split thickness — Split thickness grafts are usually used to resurface larger defects. Depending on how much of the dermis is included, STSGs undergo secondary contraction as they heal

D. Survival

1. Full thickness and split thickness skin grafts survive by the same mechanisms
 - a. Plasmatic imbibition — Initially, the skin graft passively absorbs the nutrients in the wound bed by diffusion
 - b. Inosculation — By day 3, the cut ends of the vessels on the underside of the dermis begin to form connections with those of the wound bed
 - c. Angiogenesis — By day 5, new blood vessels grow into the graft and the graft becomes vascularized
2. Skin grafts fail by four main mechanisms
 - a. Poor wound bed — Because skin grafts rely on the underlying vascularity of the bed, wounds that are poorly vascularized with bare tendons or bone, or because of radiation, will not support a skin graft
 - b. Sheer — Sheer forces separate the graft from the bed and prevent the contact necessary for revascularization and subsequent “take”
 - c. Hematoma/seroma — Hematomas and seromas prevent contact of the graft to the bed and inhibit revascularization. They must be drained by day 3 to ensure “take”
 - d. Infection — Bacteria have proteolytic enzymes that lyse the protein bonds needed for revascularization. Bacterial levels greater than 10^5 are clinically significant

E. Substitutes

1. Allograft/Alloderm — Cadaveric skin or dermis
2. Xenograft — Skin from a different species, ie pig skin
3. Synthetic — Biobrane, Integra

II. OTHER GRAFTS

- A. Nerve
- B. Fat
- C. Tendon
- D. Cartilage
- E. Bone
- F. Muscle
- G. Composite-A graft that has more than one component, i.e. cartilage and skin graft, dermal-fat graft

Flaps — Flaps are elevated from a donor site and transferred to the recipient site with an intact vascular supply. It survives by carrying its own blood supply until new blood vessels from the recipient site are generated in which the native blood supply (pedicle) can be divided. Flaps can be used when the wound bed is unable to support a skin graft or when a more complex reconstruction is needed.

I. CLASSIFICATION

- A. By composition — Flaps can be classified by the type of tissue transferred
 - 1. Single component
 - a. Skin flap — i.e. Parascapular flap
 - b. Muscle flap — i.e. Rectus muscle flap or latissimus dorsi muscle flap
 - c. Bone flap — i.e. Fibula flap
 - d. Fascia flap — i.e. Serratus fascia flap
 - 2. Multiple components
 - a. Fasciocutaneous — Radial forearm flap or anterolateral thigh flap
 - b. Myocutaneous — Transverse rectus abdominis myocutaneous flap
 - c. Osseoseptocutaneous — Fibula with a skin paddle
- B. By location — Flaps can be described by the proximity to the primary defect that needs to be reconstructed. The harvest leaves a secondary defect that needs to be closed
 - 1. Local flaps — Local flaps are raised from the tissue adjacent to the primary defect. Its movement into the defect can be described as advancement, rotation, or transposition. Specific examples of local skin flaps are the V-Y, rhomboid, and bilobed flaps

- 2. Regional — Regional flaps are raised from tissue in the vicinity but not directly adjacent to the primary defect. The movement is described as transposition or interpolation
 - 3. Distant — Distant flaps are raised from tissue at a distance from the primary defect. This usually requires re-anastomosis of the blood vessels to recipient blood vessels in the primary defect. These are called free flaps
- C. By vascular pattern
 - 1. Random vs. Axial (Figure 2-3)
 - a. Random pattern flaps do not have a specific or named blood vessel incorporated in the base of the flap. Because of the random nature of the vascular pattern, it is limited in dimensions, specifically in the length: breadth ratio
 - b. Axial pattern flaps (Fig. 2-4) are designed with a specific named vascular system that enters the base and runs along its axis. This allows the flap to be designed as long and as wide as the territory the axial artery supplies
 - i. Blood supply by direct artery and accompanying vein
 - ii. Greater length possible than with random flap
 - iii. Can be free flap (see free flap)
 - iv. Peninsular — skin and vessel intact in pedicle
 - v. Island — vessels intact, but no skin over pedicle
 - 2. Pedicled vs. Free
 - a. Pedicled flaps remain attached to the body at the harvest site. The pedicle is the base that remains attached and includes the blood supply. It is transferred to the defect with its vascular pedicle acting as a leash. Usually via a musculocutaneous or fasciocutaneous fashion
 - b. Free flaps are detached at the vascular pedicle and transferred from the donor site to the recipient site. They require re-anastomosis of the artery and vein to recipient vessels at the recipient site

3. Perforator — Perforator flaps are flaps consisting of skin and/or subcutaneous fat supplied by vessels that pass through or in between deep tissues. It is harvested without the deep tissues in order to minimize donor site morbidity and to yield only the necessary amount of skin and/or subcutaneous fat for transfer. It can be transferred either as a pedicled or free flap
 - a. Deep inferior epigastric perforator flap — DIEP flap consists of the skin and fat of the lower abdomen supplied by the deep inferior epigastric artery and vein perforators without the rectus abdominis muscle
 - b. Anterolateral thigh perforator flap — The ALTP consists of the skin and fat of the antero-lateral thigh supplied by the descending branch of the lateral circumflex artery and vein perforators without the vastus lateralis muscle
 - c. Thoracodorsal artery perforator flap — The TAP flap consists of the skin and fat of the lateral back supplied by the thoracodorsal artery and vein perforator without the latissimus dorsi muscle

- B. The failure of a flap results ultimately from vascular compromise or the inability to achieve the goals of reconstruction
 1. Tension
 2. Kinking
 3. Compression
 4. Vascular thrombosis
 5. Infection

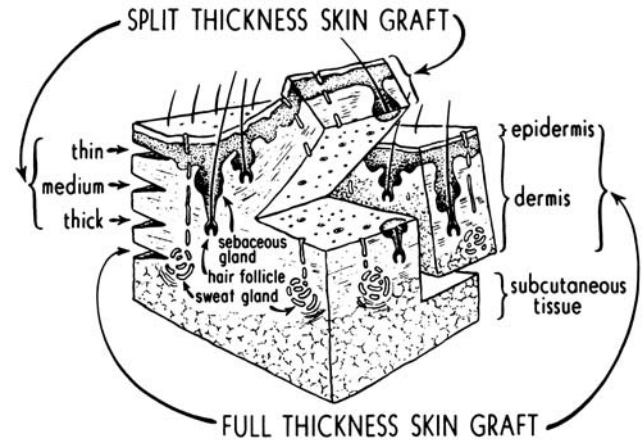


Fig. 2-1

II. CHOOSING THE RIGHT FLAP

- A. The primary defect — Recipient site considerations
 1. Location and size
 2. Quality and vascularity of surrounding tissues
 3. Presence of exposed structures
 4. Functional and aesthetic considerations
- B. The secondary defect — Donor site considerations
 1. Location
 2. Adhere to the concept of angiosomes, the territory that is supplied by a given vessel
 3. What type of tissues are needed
 4. Functional and aesthetic morbidity

III. SURVIVAL

- A. The success of a flap depends not only on its survival but also its ability to achieve the goals of reconstruction

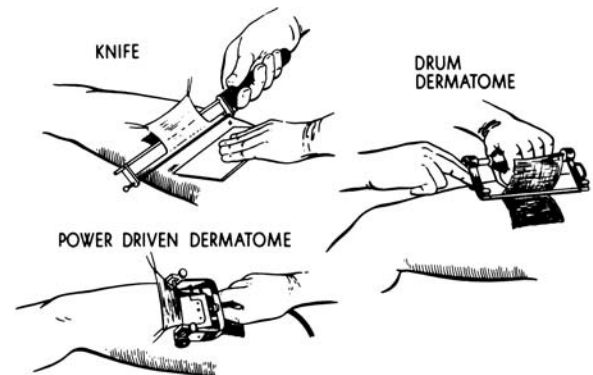
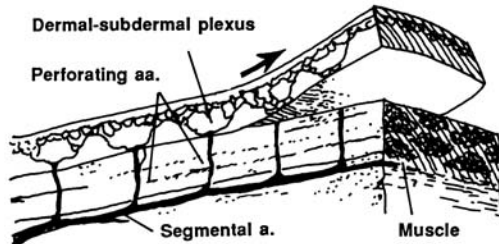
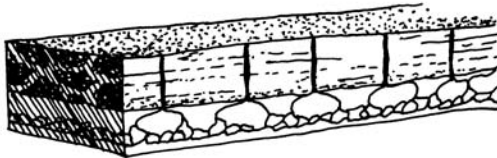


Fig. 2-2

RANDOM/RANDOM CUTANEOUS PATTERN SKIN FLAPS



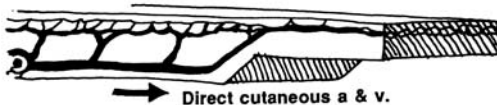
1. Random Cutaneous Flap



2. Myocutaneous Random Flap

Fig. 2-3

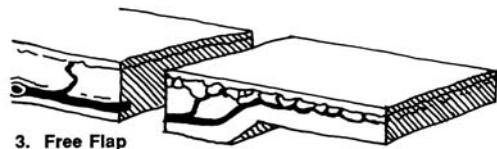
AXIAL/ARTERIAL PATTERN SKIN FLAPS



1. Peninsular Axial Pattern Flap



2. Island Axial Pattern Flap



3. Free Flap

Fig. 2-4

CHAPTER 2 — BIBLIOGRAPHY

GRAFTS AND FLAPS

1. Mathes, S.J. *Reconstructive Surgery: Principles, Anatomy and Techniques*. New York, Elsevier Science, 1997.
2. McCarthy, J.G. (ed). *Plastic Surgery, vol. 1*. New York: Elsevier Science, 1990.
3. Russell, R.C. and Zamboni, W.A. *Manual of Free Flaps* New York: Elsevier Science, 2001.
4. Serafin, D. *Atlas of Microsurgical Composite Tissue Transplantation*. New York: Elsevier Science, 1996.

CHAPTER 3

SKIN AND SUBCUTANEOUS LESIONS

Lesions can be categorized into benign or malignant types.

I. BENIGN

A. Scars

1. Hypertrophic scars. These scars are often misdiagnosed as keloid scars (see below). One can distinguish between hypertrophic and keloid scars as follows:
 - a. Hypertrophic scars are scars confined to the borders of the original incision or traumatic margins
 - b. Hypertrophic scars may regress spontaneously with time
 - c. Commonly develop in areas of tension (upper/lower extremities, back, chest)
 - d. No racial predilection
 - e. Hypertrophic fibroblasts behave as normal fibroblasts in terms of collagen and fibronectin production, as well as in terms of their response to transforming growth factor beta type-1 (TGFb1)
 - f. Treatment. Scars generally take 18-24 months to mature (reach their final appearance). Therefore hypertrophic scars can be modulated with a combination of:
 - i. Constant or intermittent pressure therapy (compression garments or massage)
 - ii. Topical silicone sheeting
 - iii. Intralesional steroid injections (10mg/ml or 40mg/ml triamcinolone, a.k.a. Kenalog-10 or Kenalog-40)
 - iv. Surgical intervention (scar revision) in select cases
2. Keloid scars. As opposed to hypertrophic scars, keloid scars have the following characteristics:
 - a. Keloid scars are scars that grow beyond the borders of the original incision or traumatic margins
 - b. Keloid scars do not regress spontaneously with time, and have a high recurrence rate

- c. Keloid scars can develop in areas of tension and nontension
- d. A racial predilection exists, as keloid scars appear more frequently in Asians and African-Americans compared to Caucasians
- e. Keloid fibroblasts produce higher levels of collagen, fibronectin, and are hyperresponsive to TGFb1
- f. Treatment. Keloid scars are difficult to treat, and are often refractory to nonsurgical and surgical therapies. Furthermore, these scars have a high recurrence rate in the setting of the various modalities of treatment
 - i. Intralesional steroids alone (9-50% recurrence rate)
 - ii. Surgery alone (45-100% recurrence rate)
 - iii. Surgery and intralesional steroids (50% recurrence rate)
 - iv. Surgery and radiotherapy (25% recurrence rate)

B. Benign Neoplasms and Hyperplasias.

1. Seborrheic Keratosis

- a. Most common of the benign epithelial tumors
- b. Usually hereditary (questionable autosomal dominant pattern)
- c. Clinically manifest after age 30
- d. More common in male population
- e. Progresses from macule (skin-colored or tan lesion in Caucasians), then progresses to plaque (“stuck-on” appearance) that is more pigmented in color. The surface may become “wartlike” and horn cysts, resulting from plugged hair follicles, arise. These cysts are pathognomonic for this keratosis.
- f. Treatment
 - i. Electrocautery, cryosurgery with liquid nitrogen spray (high recurrence rate)
 - ii. Curettage with cryosurgery (optimal modality as this does not destroy cytoarchitecture and permits histopathologic analysis)

2. Keratoacanthoma
 - a. Often confused or misdiagnosed with squamous cell carcinoma
 - b. Clinically manifests in middle years (20-50 years)
 - c. Male: female ratio 2:1
 - d. Caucasians more likely to be affected; rare in Asians and African-Americans
 - e. Isolated nodule that rapidly grows, achieving a size on average of 2.5cm within weeks. Nodule is dome-shaped, firm, red-tan in color, and has a central keratosis that sometimes gives it an umbilicated appearance
 - f. Anatomical areas of predilection: exposed skin
 - g. DDx: SCC, hypertrophic actinic keratosis, verruca vulgaris
 - h. Lesions often spontaneously regress within 2-12 months
 - i. Treatment
 - i. Single lesion: Surgical excision is often recommended (to rule out SCC)
 - ii. Multiple lesions: Retinoids and methotrexate. If no improvement, must excise
3. Dermatofibroma
 - a. A.k.a. Solitary histiocytoma, sclerosing hemangioma
 - b. Females>males
 - c. Clinically manifests in adulthood
 - d. Button-like dermal nodule, usually develops on the extremities, variable in color. Borders ill-defined. Occasionally tender
 - e. Lesions may persist or spontaneously regress
 - f. Treatment
 - i. Surgical excision rarely indicated
 - ii. Cryosurgery with liquid nitrogen spray often effective
4. Skin Tag (a.k.a. Acrochordon, or cutaneous papilla)
 - a. Common; most often present in middle aged or elderly
 - b. Intertriginous areas (axillae, groin, inframammary fold) common sites; also eyelid, neck
 - c. Clinically manifest as soft, skin-colored, pedunculated papilloma or polyp; range in size between 1-10mm. May increase in number and size during pregnancy
 - d. DDx: Pedunculated seborrheic keratosis, dermal or compound nevus, neurofibroma, or molluscum contagiosum
 - e. Treatment
 - i. Simple excision
 - ii. Cryosurgery
5. Trichoepithelioma
 - a. Common during puberty
 - b. Anatomical sites: face, scalp, neck
 - c. Clinically manifest as small skin-colored or pearl-like lesions, that increase in number and size
 - d. Can be confused with BCC (sclerosing or morpheaform-type 0.
 - e. Treatment
 - i. Surgical excision for concerning lesions
6. Syringoma
 - a. Benign adenoma of intraepidermal eccrine ducts
 - b. May be familial
 - c. Anatomical sites: face (eyelids), axillae, umbilicus, upper chest, and vulva
 - d. Most often multiple, skin-colored or yellow firm papules occurring in primarily pubertal women
 - e. Treatment
 - i. Electrosurgery.
7. Lipoma
 - a. Single or multiple benign fatty tumor(s)
 - b. Neck and trunk common sites.
 - c. Clinically manifest as soft, mobile, almost fluctuant masses that are not adherent to the skin
 - d. Treatment
 - i. Surgical excision (esp. > 5cm)
8. Verruca (wart)
 - a. Usual viral etiology (i.e., HPV)
 - b. May disappear spontaneously or respond to medical treatment
 - c. Do not excise as recurrence is likely; use cautery or liquid nitrogen

- d. Do use pulsed dye laser for recalcitrant warts
- 9. Miscellaneous
 - a. Pyogenic granuloma
 - i. Ulcerating, tumor-like growth of granulation tissue, the result of chronic infection, may resemble malignant tumor
 - ii. Treat by topical silver nitrate, excision, curettage, laser
 - b. Xanthoma (xanthelasma)
 - i. Small deposits of lipid-laden histiocytes, most common in eyelids, sometimes associated with systemic disorders (hyperlipidemia, diabetes)
 - ii. Treat by excision
 - c. Rhinophyma
 - i. Severe acne rosacea of the nose, overgrowth of sebaceous glands causing bulbous nose
 - ii. Treat by surgical planing (shaving) with dermabrasion or laser
 - d. Epidermoid (often misnamed sebaceous)
 - i. Almost always attached to overlying skin, frequently acutely inflamed if not excised
 - ii. Excise with fusiform-shaped island of overlying skin attachment (including puncture) when not inflamed
 - iii. Acutely inflamed cyst may require incision and drainage with subsequent excision
 - e. Hidradenitis suppurativa
 - i. A chronic, recurrent inflammatory disease of hair follicles (folliculitis)
 - ii. Occurs in axilla, groin and perineum and breast (intertriginous areas)
 - iii. Treatment
 - (a) In early stages, antibiotics (topical clindamycin or oral minocycline) and local care including incision and drainage of abscesses
 - (b) Later stages require excision of all involved tissue, and primary closure (associated with local recurrence) or closure by secondary intention (preferred method) or skin grafting

C. Congenital Lesions

1. Dermoid Cyst

- a. Congenital lesion usually occurring in lines of embryonic fusion (lateral 1/3 of eyebrow, midline nose, under tongue, under chin)
- c. CT scan of midline dermoid to rule out intracranial extension

2. Nevi

a. Classification

i. Intradermal (dermal)

- (a) Most common, usually raised, brown, may have hair
- (b) Essentially no potential for malignant change to melanoma
- (c) Treatment: Surgical excision necessary if concerning changes arise, or if lesion is aesthetically displeasing to patient

ii. Junctional

- (a) Flat, smooth, hairless, various shades of brown
- (b) Nevus cells most likely at basement membrane
- (c) Low malignant potential
- (d) Treatment: Surgical excision necessary if concerning changes arise, or if lesion is aesthetically displeasing to patient

iii. Compound

- (a) Often elevated, smooth or finely nodular, may have hair
- (b) Low malignant potential
- (c) Treatment: Surgical excision necessary if concerning changes arise, or if lesion is aesthetically displeasing to patient

iv. Large pigmented (bathing trunk nevus)

- (a) Congenital lesion commonly occurring in dermatome distribution
- (b) Defined as a lesion >20 sq. cm in size
- (c) Potential for malignant transformations (2-32% lifetime risk reported in literature)
- (d) Treatment: Surgical excision usually indicated. Due to large surface area,

- tissue expanders are required to recruit locoregional, unaffected skin via expanded flap transposition. Alternatives include skin grafting or laser resurfacing. It should be noted, however, with laser treatment only part of the nevus cells are ablated, which leads to destruction of local architecture. This may subvert clinical monitoring and pathologic analysis of tissue biopsies
 - v. Dysplastic nevus
 - (a) Irregular border
 - (b) Variegated in color
 - (c) Often familial
 - (d) Most likely nevus to become malignant melanoma
 - (e) Treatment: Surgical excision
 - vi. Nevus sebaceous
 - (a) Most often seen on scalp and face
 - (b) 15-20% incidence of basal cell carcinoma
 - (c) Yellowish orange, salmon-colored, greasy elevated plaque
 - (d) Treatment: Surgical excision. This can either be performed in infancy/early childhood or adolescence, as the incidence of malignancy rises after puberty
- b. Summary: Treatment of Congenital Nevi
 - i. Excision and histological examination of all suspicious pigmented lesions based on:
 - (a) Clinical appearance
 - (b) History of recent change in:
 - (i) Surface area (enlarging)
 - (ii) Elevation (raised, palpable, nodular, thickened)
 - (iii) Color (especially brown to black)
 - (iv) Surface characteristics (scaly, serous discharge, bleeding and ulceration)
 - (v) Sensation (itching or tingling)

- ii. Excision of unsightly or constantly irritated nevus (beltline, under bra or beard area)
 - iii. Careful follow-up of very large pigmented nevus, with excision of any area of change (nodularity) or staged excision of as much lesion as possible (tissue expanders and primary closure, or skin grafts when necessary)
- 3. Vascular Lesions — Most common benign tumor of infancy
 - a. Hemangioma
 - i. Hemangioma (a.k.a, strawberry nevi)
 - (a) Most common benign vascular tumor, appearing at or shortly after birth
 - (b) Three clinical phases evident: proliferative (tumor increases in size for up to 6-7 months), involutonal (stops growing, becomes gray/white in areas and then begins to regress over several or more years), and fibrotic.
 - (c) Treatment: Need for treatment rare, and depends on anatomical site and symptoms (see below). Observe frequently at first and reassure parents
 - (d) Indications for treatment: Obstructive symptoms (airway, visual), or bleeding. Systemic therapy (corticosteroids, 2mg/kg) is first line option; laser therapy may be indicated early. Interferon may be indicated for uncontrolled lesions. Surgery may eventually be indicated for removal of any disfiguring fibrofatty remnant, or in situations when bleeding is refractory to conservative measures
 - b. Malformations
 - i. Capillary malformations (port-wine stain)
 - (a) Pink-red-purple stain in skin, usually flat, but may be elevated above skin surface. Does not regress
 - (b) Treatment: Laser therapy best (flashlamp-pumped, pulsed dye laser,

- 585nm); multiple (>3) laser sessions may be necessary; surgical excision not indicated
 - ii. Arterio-venous malformation
 - (a) Large blood-filled venous sinuses beneath skin and mucous membranes. Low flow. No bruit
 - (b) Treatment: Angiography for larger and progressive lesions. Embolization with (2-3 days prior to) surgery is beneficial. Excision may be indicated
 - iii. Arterio-venous
 - (a) Progressive increase in size and extent, multiple arteriovenous fistulas, bruit
 - (b) A-V shunts or angiography
 - (c) Treatment: embolization under angiographic control by itself or prior to surgical excision
 - iv. Lymphatic
 - (a) Subcutaneous cystic tumor (cystic hygroma) of dilated vessels which can be massive and disfiguring
 - (b) May cause respiratory obstruction, may become infected
 - (c) Spontaneous regression can occur, but surgical excision is often indicated
 - (d) Lymphatic malformation can occur with arteriovenous malformation
 - v. Mixed
- C. Premalignant and Malignant Lesions of the Skin and Subcutaneous Tissue
1. Actinic or Senile Keratosis
 - a. Crusted, inflamed, history of exposed areas of face and scalp, chronic sun exposure or history of x-irradiation
 - b. Treatment: premalignant, biopsy of suspicious lesions, especially when nodular (excision), liquid nitrogen, topical chemotherapy (5-fluorouracil)
 2. Squamous cell carcinoma in situ (Bowen's Disease)
 - a. Scaly brown, tan or pink patch
 - b. Frequently associated with chronic arsenic medication
 - c. May be associated with internal malignancy
 - d. May develop into invasive squamous carcinoma
 - e. Treatment: by excision
 3. Squamous cell carcinoma
 - a. Rapidly growing (months) nodular or ulcerated lesion with usually distinct borders
 - b. Occurs on exposed areas of body and x-irradiated areas and in chronic non-healing wounds (Marjolin's ulcer). Can metastasize to regional lymph nodes (10%)
 - c. Treatment: surgical excision with adequate margins or with histologic frozen section or with Moh's micrographic surgery followed by reconstruction
 4. Basal cell carcinoma
 - a. Most common skin cancer
 - b. Types — all types may show ulceration, with rolled smooth pearly borders
 - i. Nodular — well-defined "rodent ulcer"
 - ii. Superficial
 - iii. Pigmented — resembles melanoma
 - iv. Morphea Type — sclerosing — poorly defined borders, high recurrence rates
 - c. Usually seen on face or other sun-exposed areas of body, caused by UVB ultraviolet radiation
 - d. Slow-growing (years), destroys by local invasion, particularly hazardous around eyes, ears, nose
 - e. Very rarely metastasizes
 - f. Treatment: surgical excision with adequate margins or with frozen section or with Mohs micrographic surgical excision followed by reconstruction
 5. Melanoma
 - a. Cause of great majority of skin cancer deaths
 - b. Early lymph node and systemic blood-borne metastases — frequently considered a systemic disease
 - c. Usually appears as black, slightly raised, nonulcerative lesion arising de novo or from a preexisting nevus

- d. Early recognition of changes in color, size or consistency of a pigmented nevus is critical (ABCD's = asymmetry, irregular borders, variegated color, diameter > 6mm)
- e. Classification
 - i. Pre-malignant: Lentigo maligna (Hutchinson's freckle)
 - (a) Flat, varied shades of brown pigmentation, larger than most nevi, irregular borders, smooth
 - (b) Usually slow-growing, most often on face, more frequently in elderly
 - (c) High incidence of development of invasive melanoma
 - (d) Treat by excision, with graft or flap reconstruction if necessary
 - ii. Invasive
 - (a) Lentigo maligna melanoma (10%)
 - (i) Develops in a Hutchinson's Freckle, usually as a thickened, elevated nodule
 - (b) Superficial spreading melanoma (70%)
 - (i) Flat to slightly elevated, may have a great variety of colors
 - (ii) Lesion initially spreads horizontally
 - (c) Nodular melanoma (15%)
 - (i) Characteristically blue/black in color
 - (ii) May be unpigmented (amelanotic)
 - (iii) Grows vertically, often with early surface ulceration
 - (d) Acral lentiginous melanoma (5%)
 - (i) On mucous membranes, palms, soles and subungual
 - (ii) May be amelanotic in African-Americans
- f. Histologic staging and correlation with metastases
 - i. Breslow's depth of invasion — more reliable indicator of prognosis than Clark's level (Fig. 3-1)
 - (a) Less than 0.76 mm — metastases virtually 0%
 - (b) 1.50-3.99 mm — metastases 50%
 - (c) Greater than 4 mm — metastases 66%
 - ii. Clark's levels of cutaneous invasion (Fig. 3-1)
 - (a) Level I (in situ) above the basement membrane — node metastases extremely rare
 - (b) Level II — in the papillary dermis — metastases in 2-5%
 - (c) Level III — to the junction of papillary and reticular dermis — metastases in up to 20%
 - (d) Level IV — into the reticular dermis — metastases in 40%
 - (e) Level V — into the subcutaneous tissue — metastases in 70%
 - iii. Staging
 - (a) Stage I: lesions less than 2 mm thick without ulceration
 - (b) Stage II: 1-2 mm thick with ulceration or greater than 2 mm thick with or without ulceration
 - (c) Stage III: regional node metastasis
 - (d) Stage IV: distant metastasis
- g. Treatment
 - i. Most important is the manner in which the primary lesion is removed
 - ii. Complete excisional biopsy is necessary to determine level and thickness
 - iii. Treated by "wide" excision with primary closure, split-thickness skin graft, or flap closure. Please note that permanent sections are often required to determine clear margins, and that frozen sections may not be reliable for this purpose
 - (a) Thin lesions (less than 1 mm) = 1 cm margin
 - (b) Thick lesions (greater than 1 mm) = 2 cm margin

- (c) Note that margin also depends on location and may be compromised in critical areas
 - iv. Sentinel node biopsy is used to determine regional metastases
 - v. Regional node dissection indicated for positive sentinel nodes
 - vi. Node dissection performed for palpable nodes
 - vii. Extremity perfusion may be helpful for selected cases
 - viii. Radiotherapy, chemotherapy, and immunotherapy have not been proven curative but may have some palliative effect
6. Dermatofibrosarcoma protuberans (DFSP)
- a. Rare tumor
 - b. Frequently occurs in head and neck, and genitalia (vulvar) regions
 - c. Treatment: Chemo — and radioresistant tumor. Requires wide excision to avoid recurrence (3-6cm). High recurrence rate in cases where wide local excision <3cm

CHAPTER 3 — BIBLIOGRAPHY

SKIN AND SUBCUTANEOUS LESIONS

1. Fitzpatrick T.B., Johnson R.A., Wolff K., Palano M. K., Sturmond D. Color Atlas and Synopsis of Clinical Dermatology: Common and Serious Diseases. 3rd ed. McGraw-Hill, New York. 1997.
2. Niessen F.B., Spauwen P.H.M., Schalkwijk J., Kon M. On the nature of hypertrophic scars and keloids: A review. *Plast. Reconstr. Surg.* 1999; 104: 1435-1458.
3. Cruse, C.W. and D. Reintgen: Treatment of primary malignant melanoma: A Review. *Sem Surg Onc.*, 1993; 9:215-218.
4. Eshima, I. Role of plastic surgery in the treatment of malignant melanoma. *Surg Clin North Amer.* 1996; 26:1331-1342.
5. Goldberg, D.P. Assessment and surgical treatment of basal cell skin cancer. *Clin Plast Surg.* 1997; 24:673-86.
6. Kogan, L. et al. Metastatic spinal basal cell carcinoma: a case report and literature review. *Ann Plast Surg.* 2000; 44:86-8.
7. Morganroth, G.S. and D.J. Leffell "Non-Excisional Treatment of Benign and Premalignant Cutaneous Lesions." *Clin Plast Surg.* 1993; 20:91-104.
8. Thompson, H.G. "Common Benign Pediatric Cutaneous Tumors: Timing and Treatment." *Clin Plast Surg.*, Jan 1990; 17:49-64.

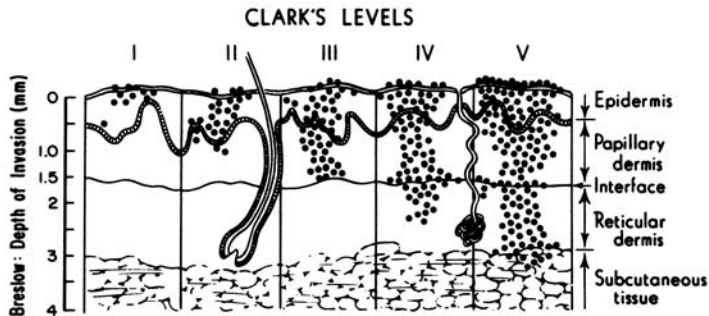


Fig. 3-1

CHAPTER 4

HEAD AND NECK

Problems of the head and neck in the practice of plastic surgery include congenital, traumatic, infectious, neoplastic, and other conditions. A working knowledge of embryology and anatomy of the head and neck is crucial in the diagnosis and surgical treatment of these diseases. Please refer to references #1 and #2 for a complete review.

I. CONGENITAL

A. Cleft Lip and Cleft Palate

1. Anatomy (Fig. 4-1)
 - a. Clefts of the lip occur in the primary palate (anterior to the incisive foramen) and may also involve the alveolar process
 - b. Clefts of the palate occur in the secondary palate, the roof of the mouth posterior to the incisive foramen and may involve hard and/or soft palate
 - c. Submucous cleft (SMCP): occult cleft of the soft palate encompassing classic clinical triad (bifid uvula, notching of the hard palate, zona pellucida)
2. Classification
 - a. Lip (Fig. 4-2)
 - i. Unilateral
 - (a) Complete
 - (b) Incomplete
 - ii. Bilateral
 - (a) Complete
 - (b) Incomplete
 - iii. Median
 - (a) Complete
 - (b) Incomplete
 - b. Palate (Fig. 4-3)
3. Prevalence
 - a. Cleft of lip with or without cleft palate (CL±CP) 1:750 in Caucasians, less in African-Americans (0.41 per 1000 live births), greater in Asians (1.41 per 1000 live births)
 - b. Cleft of palate alone (CP) 1:2500

4. Occurrence risk in offspring (Table 4-1)
5. Etiology
 - a. Multifactorial combination of heredity with or without environmental factors
 - b. Teratogenic agents — e.g. pentyntoin, alcohol
 - c. Nutritional factors may contribute — folate deficiency
6. Embryology
 - a. Cleft lip with palate forms at 4-6 weeks due to lack of mesenchymal penetration (merging) and fusion
 - b. Isolated cleft palate forms later, at 7-12 weeks, from lack of fusion
7. Pathophysiology and Functional Deficits
 - a. Cleft lip
 - i. Inability to form fluid and air seal in eating or speech
 - ii. Malocclusion as a result of intrinsic deformities of alveolar process and teeth
 - iii. Lack of continuity of skin, muscle and mucous membrane of lip with associated nasal deformity and nasal obstruction
 - iv. Deformity
 - b. Cleft palate
 - i. Inability to separate nasal from oral cavity so that air and sound escape through nose in attempted speech
 - ii. Feeding impaired by loss of sucking due to inability to create intra-oral negative pressure
 - iii. Loss of liquids and soft foods through nose due to common nasal-oral chamber
 - iv. Middle ear disease in 100% of patients due to Eustachian tube dysfunction, abnormal mucus
 - v. May be associated with Pierre-Robin sequence (cleft palate, micrognathia, glossoptosis). In these cases, airway obstruction and failure to thrive may be present. These cases may require ICU monitoring, prone positioning, nasopharyngeal airway, tongue-lip adhesion,

tracheostomy, and now mandibular distraction (moving the base of the tongue forward by mandibular advancement). Distraction has been used with some good effect in severe cases, avoiding tracheostomy

8. Team concept

Because of multiple problems with speech, dentition, hearing, etc., management of the patient with a cleft should be by an interdisciplinary team, preferably in a cleft palate or craniofacial center. Team members include: plastic surgeon, orthodontist, dentist, geneticist, pediatrician, speech therapist, audiologist, social worker, and psychologist

9. Timing of Surgical Intervention

- a. Cleft lip — most common **10 weeks** of age. Once followed “rule of 10’s” (10 weeks of age, Hgb 10, 10 lbs.), but now this rule is more historical. Range of cleft lip repair varies from **0-3 months** of age in full-term, otherwise healthy, infant
- b. Cleft palate — before purposeful sounds made (**9-12 mos**), depending upon health of infant, extent of cleft, but certainly before 18 months of age, if possible
- c. Cleft nasal deformity — most centers perform primary correction at the time of lip repair, followed by secondary work at preschool age (**4-5 years**)
- d. Alveolar cleft — most centers perform secondary bone grafting at the stage of mixed dentition (**9-12 years** of age), just before eruption of the permanent canine, which is often affected by the cleft
- e. Dentofacial skeletal abnormality — in most cleft patients, this manifests as maxillary retrusion/hypoplasia. In 25% of cleft patients, orthognathic surgery (jaw-straightening procedure) has to be performed to correct a malocclusion (abnormal bite). Orthognathic surgery can only be performed in skeletally mature individuals (**14-16 years** of age, women;

17-19 years of age, men). With the advent of craniofacial distraction, surgical intervention can be performed earlier, but both patient and parents must be advised that the growing child may “outgrow” the correction, necessitating a repeat procedure

10. Principles of Primary Repair

a. Cleft lip

- i. Repair of skin, muscle and mucous membrane to restore complete continuity of lip, symmetrical length and function
- ii. Simultaneous repair of both sides of a bilateral cleft lip
- iii. Preference for primary nasal reconstruction at time of lip repair
- iv. In wide clefts (>10mm), presurgical orthodontics (palatal appliance, nasoalveolar molding) may be indicated, or a cleft lip adhesion (surgery to initially bring lip segments together, followed by definitive repair of lip 3 months later)

b. Cleft palate

- i. One stage repair of both hard and soft palate

11. Secondary Repair

a. Cleft lip

- i. Revision of lip repair if needed
- ii. Revision of nose as required
- iii. Repair of alveolar cleft (if present) with bone graft around 9 years of age (time of eruption of canine teeth)

b. Cleft palate

- i. Correction of velopharyngeal inadequacy (nasal escape of sound and air due to remaining structural defect of palate): 4-6 years of age
- ii. Repair of any palate fistula

B. Other Congenital Anomalies

1. Craniosynostosis (343 out of 1,000,000 live births).

- a. Definition: Premature fusion of one or more cranial vault sutures. Categorized into syndromic and nonsyndromic types

- i. Nonsyndromic:
 - (a) Order of frequency according to suture type (ascending to descending): Sagittal, metopic, coronal, lambdoid, other)
 - (b) Characteristic head shape according to suture affected: Sagittal—scaphocephaly (scapho, Gr., meaning boat-shaped); metopic—trigonocephaly (trigono, Gr., meaning triangular- or keel-shaped forehead); bicoronal - brachycephaly (brachy, Gr., meaning short in AP direction)
 - (c) Ongoing debate as to whether or not these patients have an increased incidence of developmental delay
 - (d) Treatment: anterior vault reshaping (fronto-orbital advancement/reshaping), total vault reshaping, or posterior vault reshaping, depending on location and severity of craniosynostosis. Usually performed within first year of life to take advantage of molding capacity of skull
 - ii. Syndromic:
 - (a) Major associated syndromes include Apert (craniosynostosis, exorbitism, midfacial retrusion with complex syndactyly of the 2-4 digits of the hands/feet), Crouzon (craniosynostosis, exorbitism, midfacial retrusion), and Pfeiffer (craniosynostosis, exorbitism, midfacial retrusion, broad thumbs and toes) syndromes
 - (b) Characteristic head shape involves turribrachycephaly (turri-, Gr., tower)
 - (c) 50% of Apert syndrome patients have substantial mental delay; Crouzon and Pfeiffer syndrome patients usually develop normally
 - (d) Genetic defect identified in fibroblast growth factor receptor (FGFR) genes (Apert, Crouzon—FGFR2, Pfeiffer—FGFR1)
 - (e) Goals of surgery: Release fused cranial sutures, correct profound exorbitism to prevent corneal exposure/blindness, improve craniofacial dysmorphism, correct malocclusions
 - (f) Surgical interventions: Anterior/posterior/total vault reshaping (0-1 years), Monobloc (osteotomy and advance forehead and face simultaneously with bone grafts/fixation) vs. Le Fort III (osteotomy and advance face) (4-6 years), with repeating procedures as necessary. Craniofacial distraction leads to greater advancement, less relapse than conventional procedures
2. Facial Dysostoses
- a. Treacher-Collins Syndrome (Mandibulofacial Dysostosis)
 - i. Rare, autosomal dominant disorder
 - ii. Affected gene on chromosome 5q
 - iii. Variable penetrance
 - iv. Clinical manifestations: Lateral orbital wall deficiency/ midfacial retrusion due to hypoplasia/aplasia of the zygomatic bone; downward slanting palpebral fissures and colobomata; variable external ear malformations with deafness; mandibular hypoplasia with microretrognathia; underdeveloped lower jaw can lead to airway compromise, necessitating distraction or tracheostomy, or both
 - v. Treatment: Skeletal and soft tissue augmentation of deficient areas with autogenous bone (calvarium, rib, iliac crest) and autologous fat/tissue transfer, respectively. Mandibular distraction may be necessary for achieving a stable airway

- b. Hemifacial Microsomia
 - i. Third-most common congenital malformation (following club foot and cleft lip and palate)
 - ii. 1:7000 live births affected
 - iii. No genetic defect ascribed; leading theory of cause is related to disruption of the stapedial artery during embryogenesis
 - iv. Part of the oculoauriculovertebral (OAV) spectrum
 - v. Usually associated with microtia
 - vi. Manifestations include craniofacial or hemifacial deficiency, both on skeletal and soft tissue level; microtia; mandibular hypoplasia; macrostomia; malocclusion from an abnormal cant (secondary to reduced vertical height of the ramus)
 - vii. Associated with Tessier #7 facial cleft and variable facial nerve palsy
 - viii. Pruzansky classification useful for mandibular discrepancy; OMENS classification (orbit, mandible, ear, nerve, soft tissue) more comprehensive
 - ix. Treatment: Skeletal and soft tissue augmentation of deficient areas with autogenous bone (calvarium, rib, iliac crest) and autologous fat/tissue transfer, respectively. Mandibular distraction may be necessary for achieving correction of malocclusion, versus conventional orthognathic procedures to correct jaw discrepancies in adolescence
 - c. Goldenhar Syndrome
 - i. Variant of OAV spectrum
 - ii. Manifested by hemifacial microsomia, coloboma and epibulbar dermoids, vertebral spine abnormalities and renal abnormalities
 - iii. Treatment as in ii.
 - d. Nager Syndrome
3. Embryologic Defects
- a. Branchial cyst, sinus, or fistula
 - i. An epithelial-lined tract frequently in the lateral neck presenting along the anterior border of the sternocleidomastoid muscle. May present as a cyst or as a sinus connected with either the skin or oropharynx, or as a fistula between both skin and oropharynx openings
 - ii. Treatment — excision
 - b. Thyroglossal duct cyst or sinus
 - i. Cyst in the mid-anterior neck over or just below the hyoid bone, with or without a sinus tract to the base of the tongue (foramen cecum)
 - ii. Treatment — excision
 - c. Ear deformities
 - i. Types
 - (a) Complete absence (anotia) — very rare
 - (b) Vestigial remnants or absence of part of ear (microtia)
 - (c) Absence of part or all of external ear with mandibular deformity (hemifacial microsomia)
 - (d) Abnormalities of position (prominent ears)
 - ii. Treatment
 - (a) Anotia or microtia-construction from autogenous cartilage graft or synthetic implant, vascularized fascial flap, skin graft — usually requires more than one operation. (Traumatic loss of part or all of ear is treated similarly). Use of a prosthetic ear may be indicated in some patients
 - (b) Prominent ears — creation of an anthelical fold and/or re-positioning/reduction of concha
- II. TRAUMATIC**
- A. Facial soft tissue injuries
 - 1. Evaluation of all systems by trauma team (ABCDE, primary survey)

2. Establishment of airway (may be obstructed by blood clots or damaged parts) by:
 - a. Finger (jaw thrust, e.g.)
 - b. Suction
 - c. Endotracheal intubation
 - d. Cricothyroidotomy or tracheotomy
 3. Control of active bleeding by pressure until control by hemostats and ligatures or cautery in operating room
 4. Treatment of shock
 5. Very conservative debridement of detached or nonviable tissue
 6. Careful wound irrigation with physiologic solution
 7. Remove all foreign materials
 8. Palpate or explore all wounds for underlying bone injury; rule out injury to facial nerve, parotid duct, etc.
 9. Radiologic evaluation
 10. Repair as soon as patient's general condition allows with meticulous reapproximation of anatomy
 - a. Preferably less than 8 hours post-injury
 - b. Primary closure may be delayed up to 24 hours (dressing should be applied and antibiotics given while waiting)
 11. Tetanus prophylaxis
 12. Antibiotics if indicated
- B. Facial bone fractures
1. Classification
 - a. Mandible only — often bilateral (ring concept)
 - i. Depending on anatomical region (parasymphysis, body, angle, subcondyle) and overall function (malocclusion), open reduction and internal fixation (ORIF) may be indicated
 - ii. Panorex film and CT scan useful
 - iii. Key is displacement of bone segments and patient's bite
 - iv. Approximately 10-13% of fractures in the mandible coincide with c-spine fracture; so, appropriate workup (x-rays) and c-spine stabilization must be performed prior to surgery

- b. Zygomatic complex (Fig. 4-4)
 - i. Commonly associated with orbital floor fractures; therefore, must check extraocular movements and obtain ophthalmology consultation if suspicious of globe injury
 - ii. If severe displacement exists, must perform ORIF with three-point fixation
 - c. Maxillary — Le Fort I, II, III (Fig. 4-5)
 - d. Naso-orbital-ethmoidal (NOE)
 - e. Isolated orbital floor fractures: blowout versus blow-in
 - i. Check for entrapment (failure to move eye in all directions)—if present, must decompress orbit within 48 hours
 - ii. Check for enophthalmos (position of globe in relation to unaffected globe in worm's eye view). Must operate for enophthalmos 2mm or greater
 - f. Frontal sinus
 - g. Other isolated fractures — e.g. nasal
 - h. Combination of above (panfacial fracture)
 - i. Closed or open
 - j. Pediatric craniofacial fractures: Usually more conservative with operative repair in this patient population, due to growing facial skeleton and developing dentition
2. Diagnoses
- a. Consider patient history
 - b. Physical examination for asymmetry, bone mobility, diplopia, extraocular muscle entrapment, sensory loss, malocclusion, local pain
 - c. Old (pre-injury) photographs often useful to assess baseline
 - d. X-rays
 - i. Skull (rare) and cervical spine
 - ii. CT scan — axial and coronal — now imaging modality of choice
 - iii. Specialized views
 - (a) Waters view for facial bones (Fig. 4-6); good for orbital floor, now surpassed by CT

- (b) Panorex if mandibular fracture present since CT scan does not visualize mandible fractures well

3. Treatment

- a. Consultant (dentist or ophthalmologist) when indicated
- b. Re-establishment of normal occlusion is of primary importance
 - i. Use of interdental wiring, plating, or other devices in patient with teeth
 - ii. Use of patient's dentures or fabricated temporary dentures in edentulous patient
- c. Reduction and immobilization of other fractures. When dealing with panfacial fracture, handle articulating element (mandible). First by mandibulomaxillary fixation (MMF) followed by internal fixation of Mandibular fractures. Once occlusion is aligned, work systematically, either "outside-in" (Gruss) or "inside-out" (Manson), establishing facial height, width, and projection by aligning key facial buttresses
 - i. Maintain by plating with or without wiring
 - ii. In orbital floor or wall fractures, reconstitute floor and walls to prevent enophthalmos. Autogenous bone graft or alloplastic materials (titanium mesh, resorbable mesh, Medpor) are used to re-establish orbital volume

III. INFECTIONS

- A. The head and neck are relatively resistant to infection due to their robust vascularity
- B. Routes of spread
 - 1. Upper aerodigestive infections may track into the mediastinum
 - 2. Scalp and orbital infections may spread intracranially via the dural sinuses and ophthalmic veins
- C. Facial cellulitis — mostly due to staph or strep — may use a cephalosporin
- D. Oral cavity infections — mostly due to anaerobic strep and bacteroides. Use extended spectrum penicillin or other anaerobic coverage

- E. Acute Sialadenitis — fever, pain, swelling over the involved parotid gland. Seen with dehydration, debilitation, diabetics, poor oral hygiene. Treat with antibiotics, fluids
- F. Atypical mycobacteria — seen in enlarged lymph nodes; drainage rarely required. Special cultures may be necessary

IV. NEOPLASTIC (*exclusive of skin — see Chapter 3*)

A. Salivary gland tumors or disorders

- 1. Classification of tumors by location
 - a. Parotid — most common (80%), most are benign (80%)
 - b. Submandibular — 55% incidence of malignancy
 - c. Minor salivary glands — least common, with highest incidence of malignancy (about 75%)
- 2. Diagnosis
 - a. Primarily by physical examination
 - i. Any mass in the pre-auricular region or at the angle of the jaw is a parotid tumor until proven otherwise
 - b. Bimanual palpation — simultaneous intraoral and external palpation
 - c. X-rays occasionally helpful for diagnosis of stone; sialography (injection of contrast material into duct) is rarely if ever indicated
 - d. Signs more commonly seen with malignancy
 - i. Fixed or hard mass
 - ii. Pain
 - iii. Loss or disturbance of facial nerve function
 - iv. Cervical lymph node metastases

3. Treatment

- a. For stone near duct orifice
 - i. Simple removal
- b. For benign tumors (or stones in duct adjacent to gland)
 - i. Surgical removal of gland with sparing of adjacent nerves, e.g. facial nerve with parotid; lingual and hypoglossal nerves with submandibular
- c. For malignant tumors
 - i. Surgical removal of entire gland with sparing of nerve branches that are clearly

not involved

- (a) Radiation therapy if tumor not completely removed
- (b) Cervical lymph node dissection with tumors prone to metastasize to nodes

4. Pathology

a. Benign

- i. Pleomorphic adenoma — (benign mixed) high recurrence rate with local excision
- ii. Papillary cystadenoma lymphomatosum (Warthin's tumor) — may be bilateral — (10%) male, age 40-70

b. Malignant

- i. Mucoepidermoid
- ii. Malignant mixed
- iii. Adenocarcinoma

B. Tumors of oral cavity

1. Classification

- a. Anatomical — malignancies behave differently according to anatomic site and prognosis worsens from anterior to posterior

- i. Lip
- ii. Anterior two-thirds tongue
- iii. Floor of mouth
- iv. Buccal
- v. Alveolar ridge
- vi. Posterior tongue
- vii. Tonsillar fossa and posterior pharynx
- viii. Hypopharynx

b. Histopathologic

- i. Benign — according to site — fibroma, osteoma, lipoma, cyst, etc.
- ii. Malignant
 - (a) Most are squamous cell carcinoma or variants
 - (b) Palate carcinomas are often of minor salivary gland origin
 - (c) Sarcomas in mandible, tongue, other sites are rare
 - (d) TNM staging is helpful for treatment planning and prognosis (i.e. tumor size, lymph node metastases, systemic metastases)

2. Diagnosis

- a. Examination — including indirect laryngoscopy and nasopharyngeal endoscopy when indicated
- b. Biopsy of any lesion unhealed in 2-4 weeks
- c. X-rays and scans as indicated
 - i. Conventional views, panorex, etc.
 - ii. Tomography
 - iii. Computerized axial tomography
 - iv. Bone scan
 - v. Magnetic resonance imaging

3. Treatment

a. Surgical

i. Benign

- (a) Simple excision

ii. Malignant

- (a) Wide local excision with tumor-free margins
- (b) Regional lymph node dissection when indicated
- (c) Palliative resection may be indicated for comfort and hygiene
- (d) Immediate reconstruction with vascularized flaps when indicated by size and location of defect

b. Radiation therapy

i. Preoperative

- (a) To increase chance for cure, especially with large lesions
- (b) May make an inoperable lesion operable

ii. Postoperative

- (a) If tumor-free margin is questionable
- (b) For recurrence
- (c) Prophylactic — controversial
- (d) Chemotherapy — usually for advanced disease

V. MISCELLANEOUS

A. Disorders of the jaw

Generally, two categories: 1) Developmental; 2) Cleft-related

1. Deformities of the mandible

- a. Classification
 - i. Retrognathia — retrusion with respect to maxilla
 - ii. Prognathia — protrusion with respect to maxilla
 - iii. Micrognathia — underdeveloped, retruded mandible
 - iv. Open bite — teeth cannot be brought into opposition
 - v. Crossbite — lower teeth lateral to upper teeth
 - vi. Micro — and macrogenia — under- or over-development of chin
 - b. Diagnosis
 - i. Physical examination
 - ii. X-rays, including a cephalogram (lateral x-ray at a fixed distance) to measure relationships of skull, maxilla and mandible
 - iii. Dental casts are made (usually by an orthodontist) and “model” or mock surgery is performed on the casts to determine degree of advancement/setback of bone
 - c. Treatment
 - i. Establishment of normal or near normal occlusion of primary importance
 - ii. Use of osteostomies with repositioning of bone segments, bone grafts as needed, with or without orthodontic corrective measures as needed
 - iii. Mandibular distraction for severe discrepancies
2. Deformities of the maxilla
 - a. Most commonly, retrusions or under-development, “dish-face”
 - b. Must also examine the vertical height of the midface (vertical maxillary excess, VME versus vertical maxillary deficiency, VMD)
 - c. Diagnosis — as for lower jaw
 - d. Treatment — as for lower jaw
 3. Temporomandibular joint disorder
 - a. Etiology
 - i. Previous trauma

- ii. Arthritis
 - iii. Bone overgrowth
 - iv. Bruxism
 - v. Tumors
 - b. Symptoms
 - i. Pain
 - ii. Crepitus
 - iii. Joint Noises
 - iv. Limited opening
 - v. Occlusion change
 - c. Diagnosis
 - i. Consider patient history
 - ii. Examination
 - (a) Auscultation
 - (b) Opening
 - (c) Occlusion
 - iii. X-rays
 - (a) Tomograms
 - (b) Arthrogram/arthroscopy
 - (c) MRI
 - d. Treatment
 - i. Conservative: joint rest, analgesias, bite plate, etc.
 - ii. Surgery — seldom indicated
- B. Facial paralysis

Loss of facial nerve results in very significant asymmetry and deformity of the face, drooling, exposure of the cornea on the affected side. Deformity is accentuated by muscle activity of normal side (if unilateral)

 1. Etiology
 - a. Idiopathic (Bell’s palsy)
 - b. Congenital
 - c. Traumatic
 - d. Infectious
 - e. Tumor
 - f. Vascular (intracranial)
 2. Diagnosis
 - a. Demonstrated by asking patient to raise eyebrow, smile, etc.
 3. Treatment includes
 - a. Supportive — for most Bell’s palsies
 - b. Protect cornea by taping lids, lid adhesions — ophthalmology consultation is critical

- c. Re-establishment of nerve function by repair or nerve graft (sural nerve common donor nerve)
- d. Other measures, such as muscle transfers, static suspension, skin resections, free tissue transfers of muscle, etc.

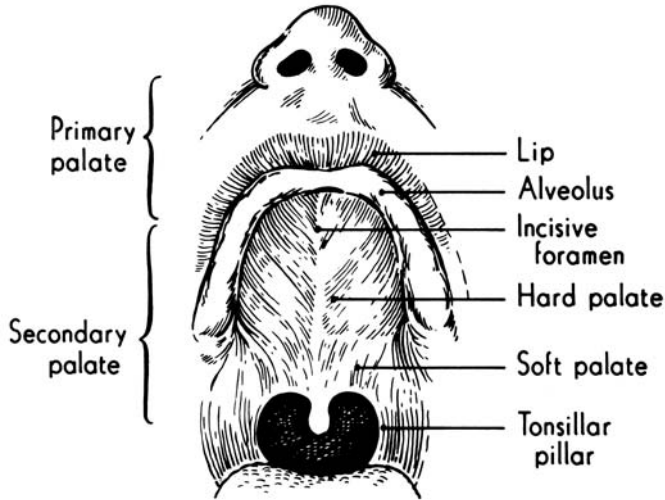


Fig. 4-1

CLASSIFICATION OF LIP CLEFTS

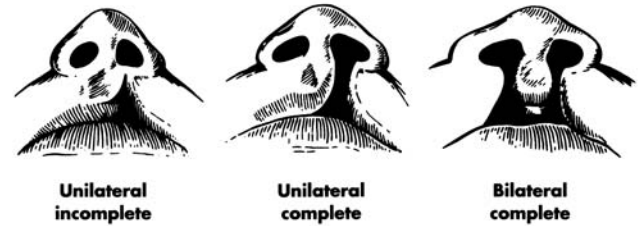


Fig. 4-2

CLASSIFICATION OF PALATE CLEFTS

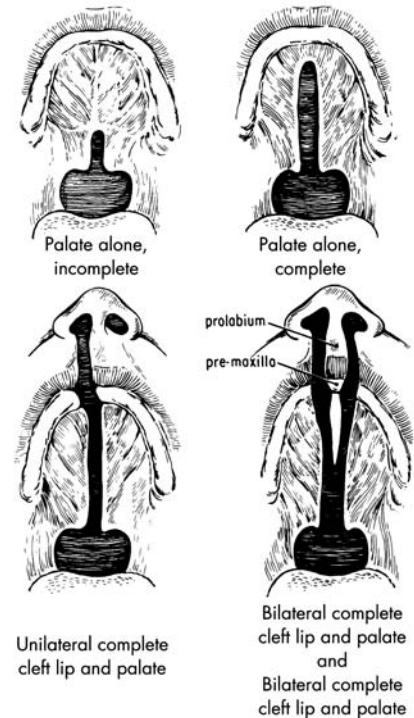


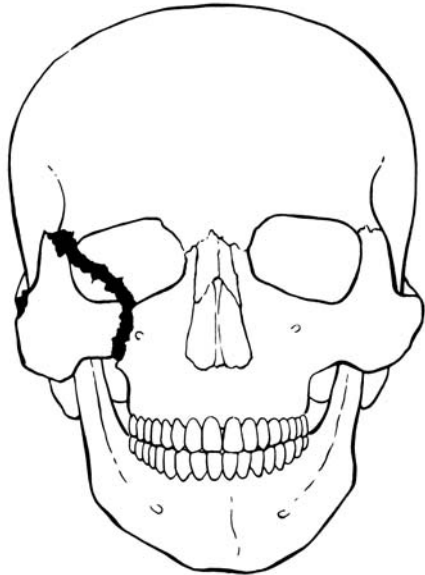
Fig. 4-3

| Affected Relatives | Predicted Outcomes* |
|----------------------|---------------------|
| <i>CL±CP</i> | |
| One sibling | ≈ 4% |
| One Parent | ≈ 4% |
| Sibling and a Parent | ≈ 16% |
| <i>CP</i> | |
| One Sibling | ≈ 2-4% |
| One Parent | ≈ 2-4 % |
| Sibling and a Parent | ≈ 15% |

Note — If congenital lip pits, inherited as autosomal dominant gene with variable penetrance (Van der Woude's Syndrome) — 50% incidence

*General predictions; individual cases may vary

Table 4-1



FRACTURE OF ZYGOMATIC COMPLEX

Fig. 4-4

WATERS VIEW

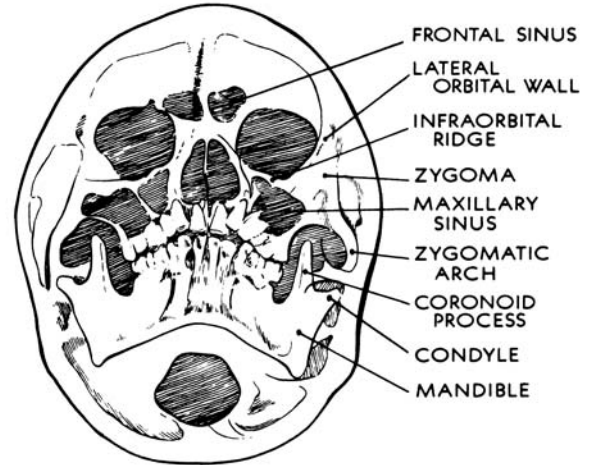
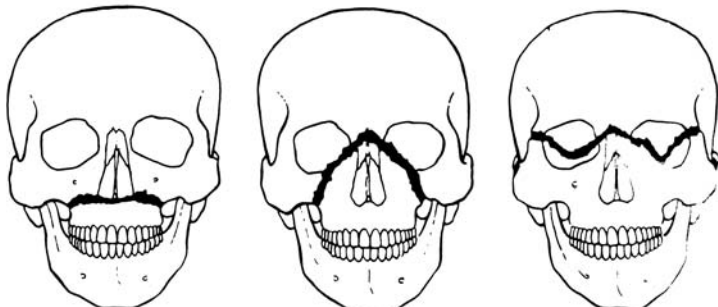


Fig. 4-6



LE FORT I
(Transverse fracture)

LE FORT II
(Pyramidal fracture)

LE FORT III
(Craniofacial disjunction)

Fig. 4-5

CHAPTER 4 — BIBLIOGRAPHY

HEAD AND NECK

1. Sperber GH. Craniofacial Development. B.C. Decker Inc., Hamilton, 2001.
2. Cohen MM: Etiology and pathogenesis of orofacial clefting. *Oral Maxillofac. Surg. Clin. No. Amer.* 2000; 12: 379-397.
3. Evans, G.R. and Manson, P.N. Review and current perspectives of cutaneous malignant melanoma. *J Am Coll Surg.* 1994; 178:523-40.
4. Gruss, J.S. Advances in craniofacial fracture repair. *Scand J Plast Reconstr Surg Hand Surg Suppl.* 1995; 27:67-81.
5. Manson PN, Hoopes, JE, Su CT. Structural pillars of the facial skeleton: An approach to the management of Le Fort fractures. *Plast. Reconstr. Surg.* 1980; 66(1): 54-61.
6. Luce, E.A. Reconstruction of the lower lip. *Clin Plast Surg.* 1995; 22:109-21.
7. Manson, P.N. et al. Subunit principles in midline fractures: the importance of sagittal buttresses, soft-tissue reductions, and sequencing treatment of segmental fractures. *Plast Reconstr Surg.* 1998; 102:1821-34.
8. Wells, M.D. et al. Intraoral reconstructive techniques. *Clin Plast Surg.* 1995; 22:91-108.
9. Williams, J.K. et al. State-of-the-art in craniofacial surgery: nonsyndromic craniosynostosis. *Cleft Palate Craniofac J.* 1999; 36:471-85.

CHAPTER 5

BREAST, TRUNK AND EXTERNAL GENITALIA

Reconstructive problems of the trunk consist of restoring chest wall and abdominal wall structural integrity after major trauma or tumor removal.

I. BREAST

A. Breast anatomy

1. Breast
 - a. Glandular tissue enclosed by superficial fascial system and deep fascia overlying chest wall muscles
 - b. Cooper's ligaments: suspensory attachment of the breast to the overlying fascia anteriorly
 - c. Boundaries:
 - i. Level of 2nd to 6th rib anteriorly
 - ii. Superior border is clavicle, inferior border is rectus abdominis fascia
 - iii. Medial border is sternum, lateral border is anterior border of latissimus dorsi muscle
2. Vasculature:
 - a. Internal mammary artery perforators (60%)
 - b. Lateral thoracic artery (30%)
 - c. Thoracoacromial artery: pectoral branches supply pectoralis major muscle and overlying breast tissue
 - d. Intercostal arteries 3, 4, 5
 - e. Venous drainage mainly to axillary vein but some to internal mammary and intercostal veins
3. Lymphatics:
 - a. 97% drainage to axilla
 - b. 3% drainage to internal mammary nodes
 - c. Level I: nodes lateral to lateral border of pectoralis minor
 - d. Level II: nodes lying beneath pectoralis minor
 - e. Level III: nodes medial to medial border of pectoralis minor and extending to apex of the axilla
4. Nerve supply
 - a. Cervical plexus: sensory branches of C3, 4 from supraclavicular nerve

- b. Lateral branches of intercostal nerves:
 - i. Provide sensation to lateral side of breast
 - ii. Lateral 4th provides major sensory innervation to nipple (T4 dermatome)
 - c. Medial branches of intercostal nerves 2-7 provide sensation to medial breast
- B. Breast reconstruction
1. All patients that have undergone mastectomy are entitled to breast reconstructive surgery
 2. The breast is a symbol of femininity
 3. Surgeon needs to understand individual needs with regard to acceptable results and range of preferences:
 - a. No reconstruction
 - b. Reconstruction to attain close to natural breast shape, feel contour
 - c. With or without nipple/areolar reconstruction
 - i. Post-mastectomy defects are usually complicated by complete loss of the nipple/areolar complex and loss of skin
 - ii. Previous irradiation may cause difficulties with wound healing, skin contraction, and discoloration
- C. Definitions
1. Subcutaneous mastectomy: removal of all breast tissue with preservation of all skin, including nipple/areolar complex. High recurrence rate if used for malignant disease
 2. Simple (total) mastectomy: removal of all breast tissue, including nipple areola complex
 3. Skin-sparing mastectomy: simple mastectomy with preservation of all skin except the nipple/areolar complex and a 1-2cm margin around the biopsy site
 4. Modified radical mastectomy: removal of all breast tissue, nipple/areola complex, pectoralis fascia, as well as Level I and II lymph nodes
 5. Halsted radical mastectomy: removal of all breast tissue, nipple/areolar complex, pectoralis major and minor muscles, muscular fascia, Level I, II, and III lymph nodes (this procedure does not improve disease control compared to modified radical mastectomy)
- D. Methods of reconstruction

1. Prosthetic:
 - a. Gradual tissue expansion with the use of subpectorally placed expanders, with eventual breast implant insertion once adequate skin expansion has occurred
 - b. Breast implants may be saline or silicone (silicone implants have long been approved by the FDA for use in patients following mastectomy and can offer a more natural feel)
2. Autogenous:
 - a. Pedicle flaps:
 - i. Latissimus dorsi myocutaneous flaps used widely (can be combined with breast implant)
 - ii. Pedicled TRAM flap using superior epigastric vessels for blood supply (rectus abdominus muscle is used as a "carrier" for the blood vessel)
 - b. Free flaps:
 - i. Technically more demanding, requiring microvascular technique
 - ii. Recipient vessels tend to be internal mammary vessels (or their breast perforators) or less commonly, the thoracodorsal vessels
 - c. Types of flaps:
 - i. TRAM (Transverse Rectus Abdominis Myocutaneous) flap
 - ii. Muscle sparing TRAM flap
 - iii. DIEP (Deep Inferior Epigastric Perforator) flap
 - iv. SIEA (Superficial Inferior Epigastric Artery Perforator) flap
 - v. The terms above represent abdominal tissue used to reconstruct the breast
 - vi. The first 3 flaps use the deep inferior epigastric vessels for blood supply, whereas the SIEA, uses the superficial inferior epigastric vessels
 - vii. SIEA has to be of adequate caliber (artery with a palpable pulse, vein >1mm) to be used for anastomosis (only 10% of women

- will have an adequate SIEP)
- viii. TRAM and the muscle sparing TRAM flaps take some element of muscle tissue as well as the fat and skin as a “carrier” for the deep inferior epigastric vessels (technically easier)
- ix. DIEP and SIEA flaps are technically harder to do as they do not take any muscle from the abdominal wall and require dissection of the blood vessels away from the “carrier” rectus abdominis muscle (advantage of no abdominal wall donor site weakness)
- x. Clinical relevance of not taking any muscle is still under debate, but may be advantageous for women who are athletic
- xi. Gluteal artery perforator flap (GAP) is another option, but is generally reserved for patients without sufficient abdominal wall tissue or patients that have previously undergone abdominal wall surgery (e.g. abdominoplasty)
- xii. Turbocharging:
 - (a) Vascular augmentation using the vascular sources within the flap territory
 - (b) Example: performing a DIEP flap to the recipient internal mammary vessels then anastomosing an additional vessel from this system
- xiii. Supercharging:
 - (a) Vascular augmentation using a distant source of vessels such as axillary or thoracodorsal vessels
 - (b) Example: performing a pedicled superior epigastric TRAM flap, then augmenting the flow by anastomosing the deep inferior epigastric vessels to the thoracodorsal vessels
- d. If desired, following unilateral breast reconstruction, the opposite breast can be contoured, using mastopexy, reduction or augmentation mammoplasty for improved

symmetry

- e. Nipple/areolar reconstruction can then be considered
 - i. Local skin flaps +/- use of cartilage or alloderm graft
 - ii. Intra-dermal color tattoo to match opposite nipple
- E. Breast reduction
 - 1. Indications:
 - a. Physical:
 - i. Neck, back, shoulder pain
 - ii. Shoulder grooving, bra straps cutting into shoulders
 - iii. Infection and maceration within inframammary fold
 - iv. Neurological sequelae
 - b. Psychological:
 - i. Embarrassment
 - ii. Self-consciousness
 - iii. Loss of sexual appeal and femininity
 - 2. Techniques:
 - a. Traditional: Wise pattern (inferior or central pedicle)
 - i. Advantage: predictable outcome
 - ii. Disadvantages: long scar length, “bottoming out” of breast, loss of superior pole
 - b. Vertical reduction pattern (superior or medial pedicle)
 - i. Advantage: attractive long term breast shape
 - ii. Disadvantages: steep learning curve, unattractive postoperative appearance
 - c. Large reductions may require nipple/areolar complex free grafting if pedicle is too long for blood supply
 - d. Liposuction can assist with “touch up”
 - 3. Outcomes:
 - a. Excellent long term satisfaction
 - b. Lactation is possible if underlying glands are preserved
 - c. Nerve supply of nipple usually preserved, but outcomes can be variable

- d. Occult breast cancer detected in 0.4% of specimens

II. CHEST WALL RECONSTRUCTION

A. Major principles:

1. Aim to restore structure and provide stable soft tissue coverage
2. Obliteration of dead space is critical in reconstruction of intrathoracic cavity
3. Aim is to restore skeletal stabilization if > 4 rib segments or > 5cm chest wall is resected *en bloc* to avoid flail chest
4. Small defects of skeletal chest wall are functionally insignificant

B. Soft tissue chest wall defects:

1. VAC therapy can be utilized
2. Regional muscle flaps most frequently used:
 - a. Pectoralis major
 - b. Latissimus dorsi
 - c. Serratus anterior
 - d. Rectus abdominis
3. Microvascular free flaps (when regional flaps have failed or are unavailable):
 - a. Contralateral latissimus dorsi
 - b. Tensor Fascia Lata
 - c. Multiple recipient vessels are available for microvascular anastomosis (e.g. thoracodorsal system)

C. Skeletal chest wall defects:

1. Prosthetic
2. Polypropylene (Prolene) mesh or Gore-tex mesh
3. Alloderm
4. Autogenous
 - a. Rib grafts, free or vascularized
 - b. Fascia
 - c. Muscle flaps (can be used without development of flail segments specifically in a radiated chest wall because of the rigidity of tissue)
5. Commonly, the use of mesh, either prosthetic or alloplastic, is used in combination with a well vascularized muscle flap for large chest wall resections requiring rigid stabilization

D. Sternal wound infection and dehiscence:

1. Mediastinitis and sternal wound dehiscence are devastating and life threatening complications of median sternotomy incision
2. Occurs in 0.25-5% of cases
3. Sternal dehiscence involves separation of the bony sternum and often infection of the deep soft tissues, referred to as mediastinitis
4. Mortality rates in initial studies near 50%
5. Treatment options:
 - a. Early debridement/wound excision
 - b. VAC therapy
 - c. Infection control with directed antimicrobial therapy based on blood and tissue culture
 - d. Development of granulation tissue
 - e. Further debridement if necessary
 - f. Rigid sternal plate fixation (provides improved chest and respiratory function as well as cosmetic appearance)
 - g. Primary rigid sternal plate fixation (in lieu of circlage wires) has been shown to decrease complications
 - h. Primary wound closure +/- myocutaneous flaps (usually pectoralis major but others have been described: rectus abdominis, latissimus dorsi and omentum)

E. Congenital chest wall defects:

1. Pectus excavatum (sunken chest) and pectus carinatum (pigeon chest)
 - a. Pectus excavatum 10 times more common than pectus carinatum
 - b. Indications for treatment:
 - i. Aesthetic
 - ii. Relief of cardiorespiratory dysfunction in severe cases
 - iii. Costal cartilage disorganized growth
 - c. Pectus excavatum treatment:
 - i. Nuss procedure:
 - (a) Curved, custom-shaped, stainless steel rod is guided through the rib cage and beneath the sternum
 - (b) Rod then rotated, turning the curved

portion against the chest wall, pushing the ribs and sternum out

- d. Pectus carinatum treatment:
 - i. Multiple osteotomies of sternum and affected ribs

E. Poland's Syndrome:

1. Etiology: subclavian artery hypoplasia
2. Features:
 - a. Absence of sternal head of pectoralis major
 - b. Hypoplasia of breast or nipple
 - c. Deficiency of subcutaneous fat and axillary hair
 - d. Bony abnormalities of anterior chest wall
 - e. Syndactyly or hypoplasia of ipsilateral extremity
 - f. Shortening of forearm
3. Treatment:
 - a. Await full breast development in girl
 - b. Breast reconstruction (flaps, implants)
 - c. Can use innervated ipsilateral latissimus to recreate anterior axillary fold

III. ABDOMINAL WALL RECONSTRUCTION

- A. Clinical problems that require abdominal wall reconstruction:
 1. Tumor resection
 2. Infection (necrotizing fasciitis)
 3. Trauma
 4. Recurrent ventral wall hernias
 5. Congenital abdominal wall defects (gastroschisis, omphalocele)
- B. Principles for abdominal wall reconstruction:
 1. To protect and cover the intra-abdominal viscera
 2. To repair and prevent herniation with strong fascial support
 3. To achieve acceptable surface contour
- C. Algorithm for abdominal wall reconstruction:
 1. Primary closure (avoid tension)
 2. Mesh (10% hernia recurrence, 7% infection)
 3. Allografts (Alloderm)
 4. Autogenous skin grafts (over viscera with or without mesh and omentum)
 5. Methods of reconstruction relying on local tissues (not applicable in patients who have had multiple

previous procedures):

- a. Components separation release
 - i. Relaxing incisions can be made unilaterally or bilaterally in the external oblique fascia, just lateral to rectus muscle
 - ii. Enables medial transposition of rectus muscle sheath
 - iii. Advancement attainable: 10cm in epigastrium, 20cm at umbilicus and 6cm in suprapubic region
 - b. Tissue expansion
6. Pedicled muscle and myocutaneous flaps (when synthetic mesh and fascial separation are contraindicated)
 - a. Tensor fascia lata
 - b. Rectus femoris
 - c. Vastus lateralis
 - d. Gracilis
 - e. Free flaps
 7. Split thickness skin and/or synthetic mesh directly over bowel (in emergency situations; requires further hernia reconstructive surgery)
 8. VAC use can be integrated into the treatment of patients with compromised wound healing
 - a. Cases of enteric fistula formation have been associated with the VAC, however, paradoxically, VAC has also been used successfully for the management of fistulas

IV. PRESSURE ULCERS

- A. Unrelieved pressure can lead to tissue ischemia in deep tissue layers near bony prominences leading to tissue necrosis
 1. Can develop within 2 hours of unrelieved pressure
 2. Decubitus was term to describe lying position, however, any area that has sustained pressure can develop into an ulcer, including the sitting position
 3. Term pressure ulcer is now preferred over decubitus ulcer
 4. Pressure sores often have "iceberg phenomenon"
 - a. Since skin can withstand ischemia much better than fat or muscle, a small skin wound on

surface can reflect a large amount of deeper tissue necrosis underneath

B. Common areas include:

1. Occipital region
2. Spine
3. Sacrum
4. Coccyx
5. Ischial tuberosity
6. Greater trochanter
7. Heel

C. Other factors contributing to pressure sore formation:

1. Altered sensory perception
2. Incontinence
3. Exposure to moisture
4. Altered activity and mobility
5. Friction and shear forces (damage to superficial layers can allow bacteria to colonize and result in deeper ulceration)
6. Muscle contractures

D. Staging system:

1. Stage I: Erythema of the skin (may be overlooked in dark-skinned patients)
2. Stage II: Skin ulceration and necrosis into subcutaneous tissue
3. Stage III: Grade II plus muscle necrosis
4. Stage IV: Grade III plus exposed bone/joint involvement

E. Incidence:

1. Bed-bound hospital patients: 10-15%
2. ICU patients: 33%
3. Hip fracture patients: up to 66%

F. Non-surgical treatment:

1. Prevention is the best treatment
 - a. Keep skin clean and dry
 - b. Appropriate nursing care, including turning the patient ever 2 hours (avoid dragging/shearing skin of the patient while repositioning)
 - c. Optimizing nutrition
 - d. Relieving pressure using air mattresses, cushions, heel protectors
 - e. Air fluidized beds (Clinitron®) gold standard for ulcer prevention

2. Systemic infection/sepsis unlikely with pressure ulcer (unless immunocompromised): look for other source e.g. urinary tract infection or respiratory tract
3. If localized infection is present (look for signs of local cellulitis) topical antimicrobial agents (Silvadene, Sulfamylon) can be used
4. Bone biopsy best method to assess osteomyelitis vs. osteitis
5. Can direct antibiotic therapy to treat osteomyelitis, but virtually impossible to eradicate infection
6. Long term antibiotics are not indicated
7. Ulcer closure may be accelerated using topical protein growth factors
8. Stage III patients require sharp debridement, highly absorptive dressings (alginates, hydrocolloid beads, foams, hydrogels)
9. VAC therapy may be beneficial to assist closure

G. Surgical treatment:

1. Due to high recurrence rates, surgery tends to be reserved for patients with reversible pathologies
2. Excisional debridement of ulcer and bursa and any heterotopic calcification
3. Partial or complete osteotomy to reduce bony prominence
4. Closure of the wound with healthy, durable tissue that can provide adequate padding over the bony prominence (myocutaneous vs. fasciocutaneous flap)

V. EXTERNAL GENITALIA

A. Congenital defects

1. Male child with congenital genital defect should not be circumcised to preserve tissue that may be needed for surgery
2. Hypospadias
 - a. Urethral opening develops abnormally, usually on the underside of the penis
 - b. Occurs in 1/350 male births
 - c. Can be associated with undescended testicles
 - d. Operation around 1 year of age (stimulation with testosterone may increase penile size and aid in wound healing)
 - e. Distal cases can be repaired using local tissue

- flaps or urethral advancement
- f. Proximal cases can be repaired using graft urethroplasty or vascularized prepuce flap urethroplasty
- 3. Epispadias and exstrophy of the bladder
 - a. Failure or blockage of normal development of the dorsal surface of the penis, abdomen, and anterior bladder wall
 - b. 1/30,000 births, three times more common in males
 - c. Epispadias treated similarly to hypospadias, with local tissue flaps
 - d. Bladder exstrophy requires staged, functional reconstruction
 - i. Neonatal period: bladder is closed
 - ii. 1-2 years: epispadia repair
 - iii. 3-4 years: bladder neck reconstruction
- 4. Ambiguous genitalia
 - a. Evaluation and management requires a team approach and great sensitivity towards the family
 - b. Caused by adrenal hyperplasia, maternal drug ingestion, hermaphroditism
 - c. Karyotype should be attained immediately
 - d. Pelvic ultrasound can be performed to assess Müllerian anatomy
 - e. Gender assignment needs to take multiple biopsychosocial factors into account
- 5. Vaginal agenesis
 - a. 1 in 5000 female births
 - b. Absence of proximal portion of vagina in an otherwise phenotypically, chromosomally, and hormonally intact female
 - c. Often undiagnosed until amenorrhea noted
 - d. Reconstruction in puberty by progressive dilation, grafts, or flaps
- B. Trauma
 - 1. Penile and scrotal skin loss injuries
 - a. Can bury shaft of penis temporarily then use full thickness or split thickness skin graft
 - b. Scrotum can have split thickness skin grafted
 - 2. Penetrating injuries to penis
 - a. Require immediate operative repair

- 3. Penis amputation
 - a. Reattachment is feasible with cold ischemia time of up to 24 hours
 - b. Debride wound and opposing surfaces thoroughly
 - c. Microsurgical approach is preferable
 - i. Urethra reapproximated with Foley as indwelling stent and suprapubic catheter for bladder drainage
 - ii. Dorsal arteries, veins, nerves reconnected
 - iii. Corpora reattached
- 4. Testicle amputation
 - a. Unilateral loss: prosthetic replacement
 - b. Bilateral loss: microsurgical replantation
- C. Phallic reconstruction
 - 1. Subtotal penile loss: release penile suspensory ligament, recess scrotum and suprapubic skin, apply skin graft to remaining stump
 - 2. Total penile loss: tubed abdominal flap, gracilis myocutaneous flap, groin flap, microvascular free flap (e.g. radial forearm, osteocutaneous fibula)
 - a. Advantages of free flap: one-stage procedure, sensation partially restored, better appearance, competent urethra, adequate rigidity
- D. Vaginal reconstruction
 - 1. Lining
 - a. Full-thickness skin grafts
 - b. Skin flaps
 - c. Intestinal segments
 - 2. Pudendal thigh flap
 - 3. Rectosigmoid vaginoplasty
- E. Infectious
 - 1. Fournier's gangrene and other necrotizing infections
 - a. Multiple organs commonly cultured
 - b. Infection begins at skin, urinary tract, rectum and spreads to penis, scrotum, perineum, abdomen, thighs, and flanks in the dartos, scarpas, and Colles fascia
 - c. Corpora bodies, glans, urethra, and testes not usually involved
 - d. Treatment primarily extensive surgical debridement of involved tissue

- e. Drains placed as deemed necessary
 - f. High dose, broad-spectrum antibiotics
 - g. Urinary diversion
 - h. Colostomy if cause from rectal/ perirectal area
2. Hidradenitis suppurativa
- a. Chronic condition
 - b. Multiple painful, swollen lesions in the axillae, groin, and other parts of the body that contain apocrine glands
 - c. Can involve adjacent subcutaneous tissue and fascia
 - d. Sinus tracts form (which can become draining fistulas) in the apocrine gland body areas
 - e. Treatment of infected lesions is incision and drainage
 - f. Cure may require massive surgical excision to eliminate all apocrine glandular tissue with healing by secondary intention
 - g. Antibiotics: Tetracycline and erythromycin may be helpful long-term

CHAPTER 5 — BIBLIOGRAPHY

BREAST, TRUNK AND EXTERNAL GENITALIA

1. Civelek B, Kargi E, Akoz T, Sensoz O. Turbocharge or supercharge? *Plast Reconstr Surg.* 1998 Sep;102(4):1303.
2. Dickie SR, Dorafshar AH, Song DH. Definitive closure of the infected median sternotomy wound: a treatment algorithm utilizing vacuum-assisted closure followed by rigid plate fixation. *Ann Plast Surg.* 2006 Jun;56(6):680-5.
3. Song DH, Wu LC, Lohman RE, Gottlieb LJ, Franczyk M. Vacuum assisted closure for the treatment of sternal wounds: the bridge between debridement and definitive closure. *Plast Reconstr Surg.* 2003 Jan;111(1):92-7.
4. Greer SE, Benhaim P, Lorenz HP, Chang J, Hedrick MH. *Handbook of Plastic Surgery.* Marcel Dekker New York 2004.
5. Aston SJ, Beasley RW, Thorne CHM. *Grabb and Smith's Plastic Surgery* 5th Edition. Lippincott Raven Philadelphia 1997.
6. Heller L, Levin SL, Butler CE. Management of abdominal wound dehiscence using vacuum assisted closure in patients with compromised healing. *Am J Surg.* 2006 Feb; 191(2):165-72.
7. Goverman J, Yelon JA, Platz JJ, Singson RC, Turcinovic M. The "Fistula VAC," a technique for management of enterocutaneous fistulae arising within the open abdomen: report of 5 cases. *J Trauma.* 2006 Feb; 60(2):428-31.
8. Garcia AD. Assessment and management of chronic pressure ulcers in the elderly. *Med Clin North Am.* 2006;90(5):925-44.
9. Walsh PC. *Campbell's Urology* 8th Edition. Saunders Philadelphia 2002.

CHAPTER 6

UPPER EXTREMITY

The surgical treatment of hand problems is a specialized area of interest in plastic surgery. The hand is a unique organ which transmits sensations from the external environment to us as well as allowing us to modify and interact with the external environment. The hand is made up of many finely balanced structures. It must function with precision, as in writing, as well as with strength, as in hammering. Since the hand is a major tool of interaction with others, it is essential that it look as normal as possible, as well as function well.

I. HAND ANATOMY

- A. Surface Anatomy — Knowledge of proper terminology is essential to communicate the location of injuries to others
- B. Nerves
 1. Sensory — median, ulnar, radial (Fig. 6-1)
 2. Motor — intrinsic muscles of hand
 - a. Median nerve — thenar muscles, radial lumbricals
 - b. Ulnar nerve — interossei, ulnar lumbricals, hypothenar muscles

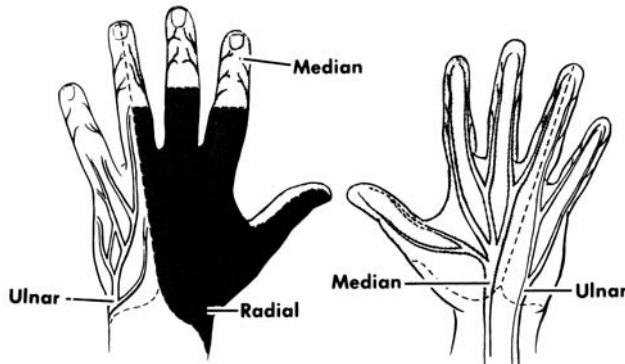


Fig. 6-1

C. Muscles and tendons

1. Flexor system (Fig. 6-2)
 - a. Long flexors — Flexor digitorum profundus attaches to distal phalanx and bends the DIP (distal interphalangeal) joint. Flexor digitorum superficialis attaches to middle phalanx and bends PIP (proximal interphalangeal) joint.
 - b. Intrinsic flexors — Lumbricals bend the MCP (metacarpal-phalangeal) joints

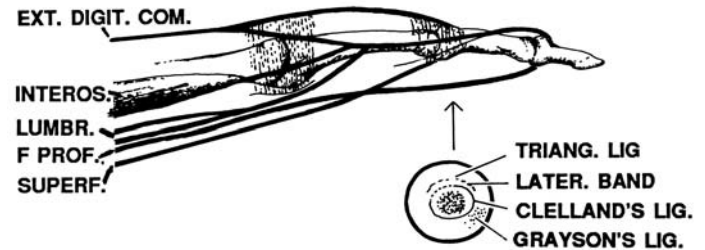


Fig. 6-2

2. Extensor system (Fig. 6-3)
 - a. Long extensors insert on base of middle phalanx
 - b. Intrinsic (interossei and lumbricals) pass volar to the axis of the MCP joint (where they act as flexors) and move dorsal to the axis of the PIP joint to insert on the dorsal distal phalanx. They act as extensors to the PIP and DIP joints

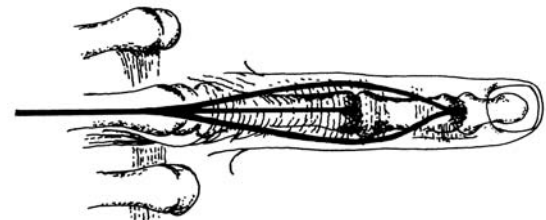


Fig. 6-3

D. Skeleton (Fig. 6-4 — see bibliography page 80)

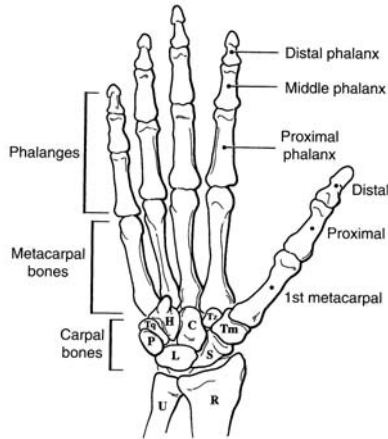


Fig. 6-4*

E. Wrist — a large number of tendons, nerves and vessels pass through a very small space, and are vulnerable to injury (Fig. 6-5)

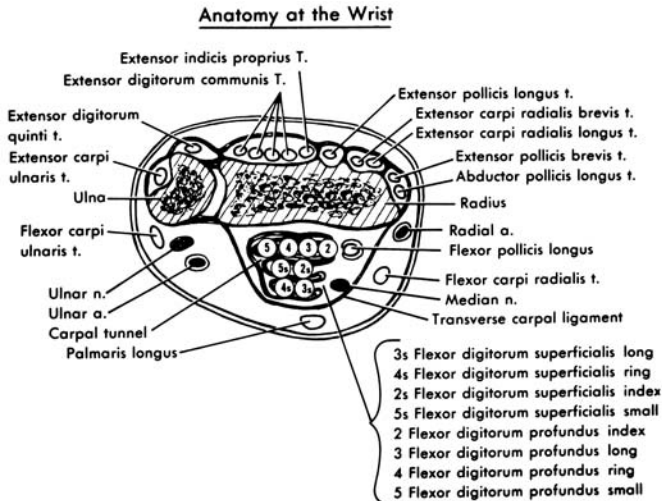


Fig. 6-5

II. INITIAL EVALUATION OF THE INJURED HAND

A. History

1. Time and place of accident
2. Agent and mechanism of injury
3. First aid given
4. Right or left hand dominance
5. Occupation
6. Age

B. Examination

1. Observation

- a. Position of fingers — normally slightly flexed. An abnormally straight finger might indicate a flexor tendon injury (the unopposed extensors hold the finger straight)
- b. Sweating patterns (indicate innervation)
- c. Anatomic structures beneath the injury

2. Sensory — must test prior to administering anesthesia

- a. Pin to measure sharp/dull sensitivity, paper clip to measure two point discrimination
- b. Test all sensory territories (median, ulnar, radial)
- c. Test both sides of each finger

3. Motor

- a. Profundus — stabilize PIP joint in extension, ask patient to flex fingertip (Fig. 6-6)
- b. Superficialis — stabilize other fingers in extension. This neutralizes profundus action. Ask patient to flex finger (Fig. 6-7)
- c. Motor branch of median nerve: test palmar abduction of thumb against resistance
- d. Motor branch of ulnar nerve: ask patient to fully extend fingers, then spread fingers apart
- e. Extensor tendons
 - i. Ask patient to extend fingers at MCP joints (tests long extensors)
 - ii. Ask patient to extend PIP, DIP joints with MPs flexed (tests intrinsic extensors)

TESTING PROFUNDUS

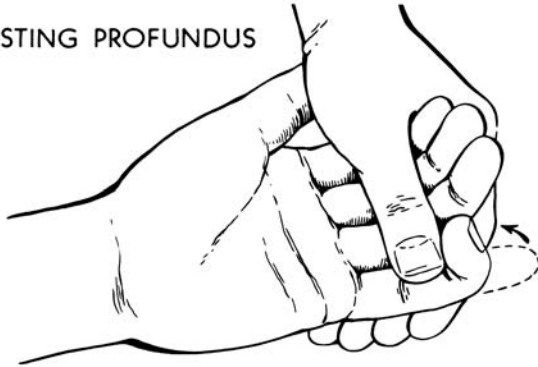

Fig. 6-6

TESTING SUPERFICIALIS

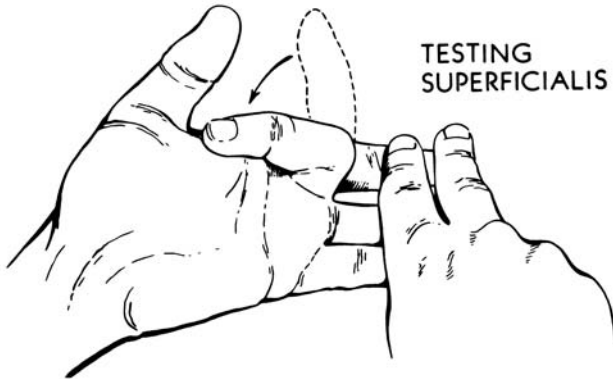


Fig. 6-7

4. Vascular
 - a. Color — nailbed should be pink, blanch with pressure, and show capillary refill within one second
 - b. Temperature — finger or hand should be similar in temperature to uninjured parts
 - c. Turgor — pulp space should be full without wrinkles

C. Early care

1. Use pneumatic tourniquet or BP cuff inflated to 250mmHg to control bleeding for examination and treatment. An awake patient will tolerate a tourniquet for 15-30 min
2. If bleeding is a problem, apply direct pressure and elevate until definitive care available
 - a. Do not clamp vessels
 - b. Tourniquet may be used as last resort, but must be released intermittently
3. Splint in safe position if possible (Fig. 6-8)
 - a. Position where collateral ligaments are at maximum stretch, so motion can be regained with least effort
 - b. Positioning — wrist extended (45°), MCP joints flexed (60°), IP joints straight, thumb abducted and rotated in opposing position
 - c. Proper splinting prevents further injury, prevents vessel obstruction, prevents further tendon retraction
4. All flexor tendon, nerve and vascular injuries, open fractures, and complex injuries are managed in the operating room
5. Tetanus prophylaxis and antibiotic coverage as indicated

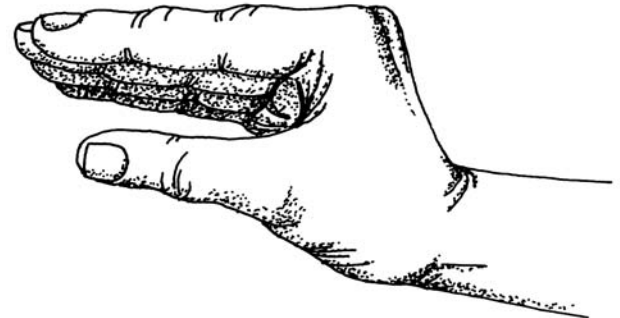


Fig. 6-8

D. Definitive treatment

1. Thorough cleaning of entire hand and forearm, with wound protected
2. Apply sterile drapes
3. Inspect wound — use tourniquet or BP cuff for hemostasis
4. Wound irrigation with normal saline
5. May need to extend wound to inspect all vital structures
6. Assure hemostasis with fine clamps and cautery
7. Nerve injuries should be repaired with magnification
8. Tendons are repaired primarily, except in special instances (e.g. human bite)
 - a. Flexor tendon injuries in Zone II, “no man’s land” (Fig. 6-9) should be repaired by a trained hand surgeon
 - b. If a hand surgeon is not available, clean and suture the skin wound, splint the hand, and refer as soon as possible for delayed primary repair. Repair needs to be done within 10 days
9. Reduce fractures and dislocations, apply internal or external fixation if needed
10. Postoperative dressings
 - a. Splinting should be in safe position when possible, but alternative positioning may be required to protect tendon or nerve repairs
 - b. Dressings should not be tight

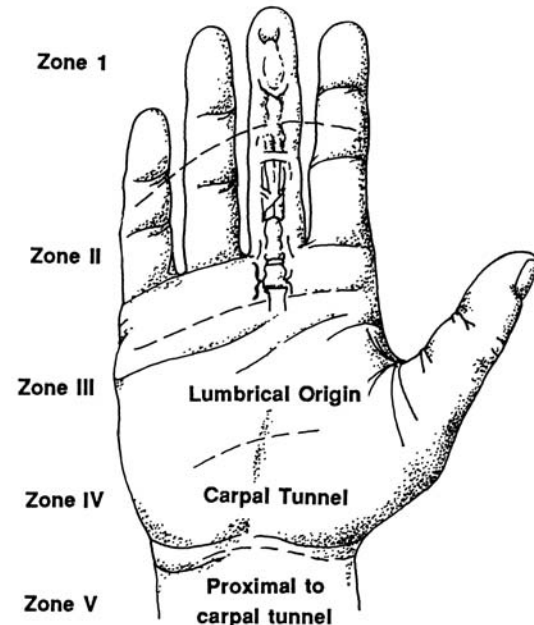
III. SPECIAL INJURIES

A. Fingertip — most common injury

1. Tip amputations
 - a. Basic principles — maintain length, bulk and sensibility
 - b. Treatment options include secondary healing, skin graft, flap
2. Nailbed injury
 - a. Nailbed should be repaired with fine chromic gut suture
 - b. Nail can be cleaned and replaced as a splint, or silastic sheet used as splint to prevent adhesion of the eponychial fold to the nailbed

B. Amputation

1. Indications for replantation — thumb, multiple fingers. Single finger replantations often not indicated. Must discuss with replant team
2. Care of amputated part
 - a. Remove gross contamination and irrigate with saline
 - b. Wrap part in gauze moistened in saline, place in clean plastic bag or specimen cup, seal
 - c. Lay container on ice, or float on ice cubes in water. Don’t immerse part directly in ice water or pack directly in ice — it may freeze



Flexor zones of hand.

Fig. 6-9

3. Care of patient
 - a. Do not clamp vessels — use direct pressure so as not to injure digital nerve
 - b. Supportive care
 - c. X-ray stump and amputated part
- C. Burned hand
 1. Initial treatment
 - a. Cleanse wound, debride broken blisters
 - b. Evaluate blood supply — circumferential full thickness burns may require escharotomy
 - c. Apply occlusive dressings to reduce pain
 - d. Immobilize in safe position
 - e. Refer to plastic surgeon if burn is extensive or may require grafting
 2. Hand therapy may be needed to maintain motion

IV. INFECTIONS

- A. General principles
 1. Infection can be localized by finding:
 - a. The point of maximum tenderness
 - b. Signs of local heat
 - c. Overlying skin edema
 - d. Pain on movement
 2. A fever usually denotes lymphatic involvement
 3. Pressure from edema and pus in a closed space can produce necrosis of tendons, nerves and joints in a few hours. Extreme cases can lead to amputation and even death
- B. Treatment principles
 1. Surgical drainage, cultures
 2. Immobilization in safe position, elevation
 3. Antibiotics
- C. Specific infections
 1. Paronychia — infection of the lateral nail fold
Treatment: if early, elevation of skin over nail to drain. If late, with pus under nail, must remove lateral portion of nail
 2. Felon
 - a. Pus in pulp space of fingertip — closed space without ability to expand — very painful
 - b. Pressure of abscess may impair blood supply

- c. Treatment is drainage over point of maximal tenderness — lateral if possible
3. Subcutaneous abscess — incise and drain with care not to injure digital nerve. Be alert to possibility of foreign body
4. Tenosynovitis — infection of tendon sheath
 - a. Diagnostic signs (Kanavel's signs)
 - i. Fusiform swelling of finger
 - ii. Finger held in slight flexion
 - iii. Pain with passive extension
 - iv. Tenderness over flexor tendon sheath
 - b. Treatment is to open and irrigate tendon sheath. Untreated infection can destroy the tendon within hours
5. Human bite
 - a. Have high index of suspicion — patients are often unwilling to admit being in a fight. Most common site over a knuckle
 - b. Debride, cleanse thoroughly, culture
 - c. Must rule out penetration of joint space — may need to explore in OR
 - d. Broad spectrum antibiotics — often I.V.
 - e. Do not suture wound

V. FRACTURES

- A. General principles
 1. Inspect, palpate, x-ray in multiple planes — AP, true lateral, oblique
 2. Reduce accurately
 3. Immobilize for healing
 4. Hand therapy to maintain motion
- B. Specific fractures
 1. Metacarpal fractures
 - a. Boxer's fracture — fracture of 4th or 5th metacarpal neck. Can accept up to 30 degrees of angulation. Treatment can range from gentle protective motion if minimally displaced to closed reduction and cast to open reduction and internal fixation
 - b. Metacarpal shaft fractures — must check for rotatory deformity. Flex all fingers. If involved finger overlaps another, there is rotation at the

fracture site which must be reduced. Unstable fractures must be fixed with pins or plates and screws

2. Phalangeal fractures
 - a. Unstable fractures require internal or percutaneous fixation
 - b. Joint surfaces should be anatomically reduced
3. Tuft fractures (distal phalanx)
 - a. If crushed, mold to shape
 - b. Repair associated nailbed injury if needed
 - c. Splint for comfort (DIP only) for 1-2 wks

VI. JOINT INJURIES

- A. Dislocation
 1. If already reduced, test for instability in range of motion and with lateral stress
 2. Most can be treated with closed reduction; open reduction can be necessary if supporting structures entrap the bone (e.g. metacarpal head through extensor mechanism)
- B. Ligamentous injury — usually lateral force
 1. Gameskeeper's thumb — rupture of ulnar collateral ligament of MP joint
 2. Wrist injury — multiple ligaments can be involved. Diagnosis may require arthrogram, arthroscopy, or MRI. Clinical diagnosis by pattern of pain, x-rays, palpation for abnormal movement
- C. Treatment
 1. Try to maintain controlled protected motion
 2. Unstable joint — immobilize for 3 wks. (some, e.g. thumb ulnar collateral ligament, might need operative repair)

VII. CONGENITAL DEFECTS

- A. Classification system (Table 6-1)
- B. Common defects
 1. Polydactyly — most common. Duplication of fingers, usually border digits. Duplication of 5th finger is common autosomal dominant trait in African-Americans. Thumb duplication often requires reconstructive surgery
 2. Syndactyly — 2nd most common — May be simple,

involving skin only, or complex, involving bone

- C. Treatment — goal to decrease deformity and improve function
 1. Some problems are treated in infancy — e.g. splinting for club hand, thumb reconstruction
 2. Some treated in early childhood — e.g. separation of syndactyly
 3. Some require multi-staged procedures — e.g. club hand

- I. Failure of formation of parts
 - A. Transverse
 - B. Longitudinal
- II. Failure of separation of parts
- III. Duplication of parts
- IV. Overgrowth of parts
- V. Undergrowth of parts
- VI. Congenital constriction bands
- VII. Generalized skeletal abnormalities

Adapted from Swanson, A.B.: *J Hand Surg* 1:8, 1976.

Table 6-1

VIII. HAND TUMORS

- A. Benign
 1. Ganglion cysts — most common
 - a. Synovial cyst of joint or tendon sheath
 - b. Treatment is excision
 2. Giant cell tumor
 3. Glomus tumors — of thermoregulatory neuromyoarterial apparatus. Presents with pain and temperature sensitivity
 4. Bone tumors — enchondroma, osteoid, osteoma
- B. Malignant
 1. Skin cancers (e.g. basal cell, squamous cell, melanoma)
 2. Malignant bone tumors are uncommon in hand

IX. MISCELLANEOUS

- A. Rheumatoid arthritis — synovial hypertrophy can lead to nerve compressions (carpal tunnel syndrome), joint destruction. Hand surgeons get involved with synovectomy, joint replacement, carpal tunnel release
- B. Dupuytren's contracture
 1. Fibrous contraction of palmar fascia causes flexion contractures of fingers
 2. Treatment is surgical excision of involved fascia
- C. Nerve compressions — compression of nerve by overlying muscle, ligament or fascia
 1. Example: carpal tunnel — compression by transverse carpal ligament
 2. Diagnosis by symptoms and EMG
 3. Treatment options include splinting, steroid injections, surgery

CHAPTER 6 — BIBLIOGRAPHY

UPPER EXTREMITY

1. Achauer, B.H. *Plastic Surgery: Indications, Operations, Outcomes*. St. Louis: Mosby, 2000.
2. Aston, S.J. et al. (eds.) *Grabb and Smith's Plastic Surgery*. 5th Ed. Baltimore: Lippincott, Williams and Wilkins, 1997.
3. Green, D.P. *Operative Hand Surgery*. New York: Churchill Livingstone, 1996.
4. McCarthy, J. *Plastic Surgery*. (8 vols). St. Louis: Mosby, 1990.

*Fig. 6-4 reprinted with permission from Marks, M.W., Marks, C. *Fundamentals of Plastic Surgery*. Philadelphia: W.B. Saunders Co., 1997.

CHAPTER 7

LOWER EXTREMITY

The plastic and reconstructive surgeon is often called upon to treat many wound problems of the lower extremity. These include leg ulcers of various etiologies, trauma with extensive soft tissue loss or exposed bone, vascular or neural structures, and lymphedema.

I. ULCERATIONS

An ulcer is an erosion in an epithelial surface. It is usually due to an underlying pathophysiological process. The proper treatment depends upon the etiology

A. Etiology

1. Venous Stasis Ulcer
 - a. Due to venous hypertension: related to venous valvular incompetence — usually found over the medial malleolus
 - b. Increased edema
 - c. Increased hemosiderin deposition (dark discoloration)
 - d. Not painful
2. Ischemic Ulcer
 - a. Due to proximal arterial occlusion
 - b. Usually more distal on the foot than venous stasis ulcers
 - c. Most often found on the lateral aspects of the great and fifth toes, and the dorsum of the foot
 - d. No edema
 - e. No change in surrounding pigmentation
 - f. Painful
 - g. Doppler ankle/brachial indices 0.1-0.3
 - h. Indicates advanced atherosclerotic disease
 - i. Dirty, shaggy appearance
3. Diabetic Ulcer
 - a. Due to decreased sensation (neurotrophic) or occasionally decreased blood flow
 - b. Usually located on plantar surface of foot over metatarsal heads or heel
 - c. Edema ±
 - d. No change in surrounding pigmentation

4. Traumatic Ulcer Surgical treatment requires excision of the entire area of the ulcer, scar tissue, and surrounding
 - a. Failure to heal is usually due to compromised blood supply and an unstable scar
 - b. Usually occurs over bony prominence
 - c. Edema ±
 - d. Pigmentation change ±
 - e. Pain ±
 5. Pyoderma Gangrenosum
 - a. Frequently associated with arthritis and/or inflammatory bowel disease or an underlying carcinoma
 - b. Clinical diagnosis — microscopic appearance non-specific
 - c. Zone of erythema at advancing border of the lesion
- B. Treatment

Each ulcer type requires accurate diagnosis, specific treatment of the underlying etiology, and care of the wound. Not all ulcers of the lower extremity will require surgical intervention when appropriate management is pursued. The key to healing these ulcers is wound hygiene, correction of the underlying problem, and specific surgical intervention when appropriate. The plastic surgeon is an integral member of the treatment team from the onset of the problem. Remember that two different predisposing conditions may occur in the same patient. If so, the treatment must address both conditions

1. Venous Stasis Ulcers
 - a. Most will heal if venous hypertension is controlled
 - b. Decrease edema with constant bed rest with foot elevation
 - c. Clean wound 2-3 times a day with soap and water
 - d. Topical antimicrobials may be required
 - e. Systemic antibiotics are required if cellulitis is present or bacteremia occurs
 - f. “Unna boots” may heal ulcers in patients who are noncompliant with bed rest or must continue to work. These are changed on a

- weekly or bi-weekly basis
 - g. Surgical treatment requires excision of the entire area of the ulcer, scar tissue, and surrounding area of increased pigmentation (hemosiderin deposition). Subfascial ligation of venous perforators is also performed
 - i. Skin grafting of large areas is usually not a problem. Intact periosteum or paratenon will take a graft well
 - ii. Free flaps can be effective for recalcitrant ulcers
 - h. Pressure gradient stocking (such as Jobst™ garments) and a commitment to avoiding standing for long periods of time are necessary for long term success
2. Ischemic Ulcers
 - a. Most require revascularization based upon angiographic findings
 - b. Control associated medical problems such as congestive heart failure, hypertension, diabetes, etc.
 - c. Bed rest without elevation of the foot of the bed
 - d. Topical and/or systemic antibiotics are usually required
 - e. If possible, it is best to perform bypass surgery first, and then healing of the ulcer by any means will be easier
 - f. Usually a skin graft will close the wound; flap closure may be required. A more proximal amputation may be required if revascularization is not possible
 3. Diabetic Ulcer
 - a. Debride necrotic tissue and use topical and systemic antibiotics to control the infection
 - b. Be conservative in care; early amputation is detrimental since many patients will have life-threatening infections in the other leg within a few years
 - c. After control of bacterial contamination, small ulcers may be excised and closed primarily; larger ulcers may require flap coverage

- d. Treatment should also include resection of underlying bony prominence
 - e. Rule out proximal arterial occlusion and improve arterial inflow when needed
 - f. Postoperative diabetic foot care at home is paramount to proper management. Patient education in caring for and examining their feet is extremely important
4. Traumatic Ulcer
- a. Nonhealing is usually secondary to local pathology
 - b. Resection of the ulcer, thin skin, and unstable scar is required
 - c. Reconstruction with a local or distant flap is required
5. Pyoderma Gangrenosum
- a. Very difficult
 - b. May include anti-inflammatory drugs or immunosuppressives, as well as local wound care agents
 - c. Success in treatment has been reported with hyperbaric oxygen in conjunction with local wound care

II. TRAUMA

Lower extremity trauma is frequently very complex, and often requires a team approach involving the orthopedic, vascular and plastic surgeons. Limb salvage with bipedal ambulation and normal weight bearing is the goal of all surgical intervention

A. Initial Management

1. All patients with lower extremity trauma should be evaluated for associated injuries, and treated according to ATLS criteria
2. All life threatening injuries (intracranial, intrathoracic, and intra-abdominal) should be addressed initially in the operating room
3. Surgical debridement of the wound in the operating room and irrigation with pulsatile jet lavage of a physiologic solution is the proper initial management. Specific management depends upon

the level of injury, presence or absence of bony and neurological injury

4. Limb threatening injuries of vascular interruption or open fracture are best assessed in the OR with radiologic backup
 5. Fasciotomy is often required to maintain tissue perfusion in severe high energy or crush injuries
 6. Intra-operative evaluation for viability utilizing visual and surgical techniques may be supplemented by intravenous fluorescein to assess the viability of degloved tissue
- B. Level of Injury
1. Thigh

Usually managed with delayed primary closure or skin graft. An abundance of soft tissue in the thigh makes coverage of bone or vessels rarely a problem

 - a. Open joint wounds are usually managed by the orthopedic service with profuse lavage and wound closure
 - b. Extensive soft tissue loss will often require flap rotation — the tensor fascia lata, gracilis, rectus femoris, vastus lateralis, and biceps femoris are primarily utilized
 - c. The medial and lateral heads of the gastrocnemius muscle are most often utilized to cover an open knee joint
 2. Lower Leg
 - a. Paucity of tissue in the pre-tibial area results in many open fractures which cannot be closed primarily
 - b. General principles of wound closure and achieving bacterial balance prevail
 - c. Delayed primary closure, healing by secondary intention, or skin grafts are good alternatives in the management of wounds where bone or fractures are not exposed
 - d. Rigid fixation with vascularized tissue coverage is necessary for bone healing
 - e. Fractures of the lower leg are usually classified by the Gustilo system (Table 7-1)
 - i. Type I and II fractures usually have a good outcome with varied treatment

Gustilo Classification of Open Fractures of the Lower Leg

| | |
|-----------|--|
| Type I | Open tibial fracture with a wound less than one centimeter |
| Type II | Open tibial fracture with a wound greater than one centimeter, without extensive soft tissue damage |
| Type IIIA | Open tibial fracture with adequate soft-tissue coverage despite extensive laceration or flaps, or high-energy injury accompanied by any size wound |
| Type IIIB | Open tibial fracture, extensive soft-tissue loss with periosteal stripping and bone exposure |
| Type IIIC | Open tibial fracture with arterial injury requiring repair |

Table 7-1

- ii. Gustilo Type III injuries have a worse prognosis
- f. Depending on the level of injury, different muscle flaps can be used to close the wounds
 - i. Proximal 1/3 of tibia
 - Medial head of the gastrocnemius muscle
 - Lateral head of the gastrocnemius muscle
 - Proximally based soleus
 - ii. Middle 1/3 of tibia
 - Proximally based soleus
 - Flexor digitorum longus muscle
 - Extensor hallucis longus muscle
 - iii. Lower 1/3 of tibia
 - Microvascular free tissue transfer
- g. Fasciocutaneous flaps are another alternative for closure of difficult wounds in the lower leg
- 3. Foot
 - a. Split thickness skin grafts should be used if bone not exposed
 - b. The heel may be covered by medial or lateral plantar artery flaps
 - c. Forefoot — toe fillet and plantar digital flaps

- 4. The technical feasibility of lower extremity reconstruction must be weighed against the option of amputation with early prosthesis fitting and ambulation. Extensive injuries may lead to rehabilitation and non-weight bearing of up to two years, and late complications may still require amputation

III. LYMPHEDEMA

Lymphedema may be a congenital or acquired problem, and results in accumulation of protein and fluid in the subcutaneous tissue. It may be a very debilitating and disfiguring disease, and at this time has no good surgical answer

A. Primary (idiopathic)

- 1. Female: Male = 2:1
- 2. Classification — depends on age of onset
 - a. Congenital — present at birth
 - i. Milroy's disease — familial autosomal dominant incidence
 - ii. 10% of all primary lymphedema
 - b. Lymphedema praecox
 - i. Usually a disease of females
 - ii. 80% of all primary lymphedema
 - iii. Appears at puberty or early adulthood
 - iv. Localized swelling on dorsum of foot that gets worse with activity
 - v. Meige's disease presents with significant symptoms of acute inflammation
 - c. Lymphedema tarda
 - i. Appears in middle or later life
- 3. Diagnosis
 - a. By history — sometimes hard to discern a component of venous stasis from the lymphedema
 - b. Lymphangiogram — 70% have hypoplasia, 15% aplasia and 15% hyperplasia

B. Secondary: Acquired — Usually secondary to pathology in the regional lymph nodes

- 1. Wucheria bancrofti — number one cause of lymphedema worldwide
- 2. Post traumatic or post surgical

3. Secondary to regional node metastases
4. Treatment
 - a. Nonoperative
 - i. Preferable in most circumstances and many patients are managed quite well
 - ii. Elevation and elastic support are the mainstays of therapy — intermittent compression machines may be of benefit
 - iii. Use of steroids controversial
 - iv. Benzopyrones may be of benefit in high protein lymphedema
 - v. Antiparasitic medications are indicated when appropriate
 - vi. Systemic antibiotics and topical antifungal medications are often required
 - b. Surgical management
 - i. Ablative procedures — usually involve excision of tissue and closure with a flap or skin graft
 - ii. Attempted re-establishment of lymphatic drainage by microvascular techniques has shown early improvement, but is prone to high, late failure rate. May offer hope for patients with secondary lymphedema in the future

CHAPTER 7 — BIBLIOGRAPHY

LOWER EXTREMITY

1. Heller, L. and Levin, S.L. Lower extremity microsurgical reconstruction. *Plast Reconstr Surg.* 2001; 108:1029-41.

CHAPTER 8

THERMAL INJURIES

Thermal destruction of the skin results in severe local and systemic alterations. This destruction can occur from thermal energy, chemical reactions, electricity, or the response to cold. The management of the patient with a major thermal injury requires understanding of the pathophysiology, diagnosis, and treatment not only of the local skin injury but also of the derangements that occur in hemodynamic, metabolic, nutritional, immunologic, and psychologic homeostatic mechanisms.

I. BURNS

- A. Pathophysiology: Amount of tissue destruction is based on temperature ($>40^{\circ}\text{C}$) and time of exposure (Fig. 8-1)
- B. Diagnosis and prognosis
 1. Burn size: % of total body surface area (TBSA) burned
 - a. Rough estimate is based on rule of 9s (Fig. 8-2)
 - b. Different charts are required for adults and children because of head-chest size discrepancy and limb differentials for ages birth to seven years (Fig. 8-3 and 8-4)

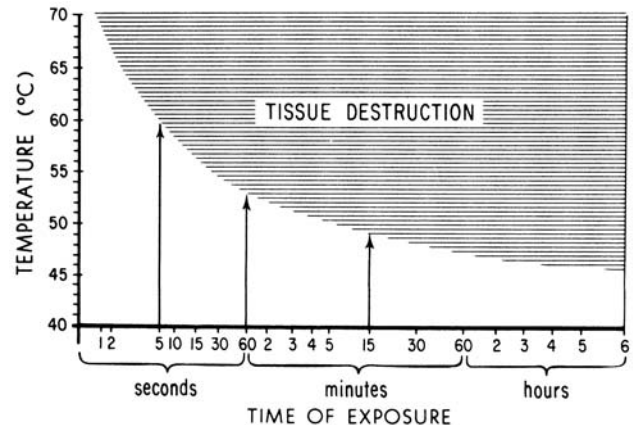


Fig. 8-1

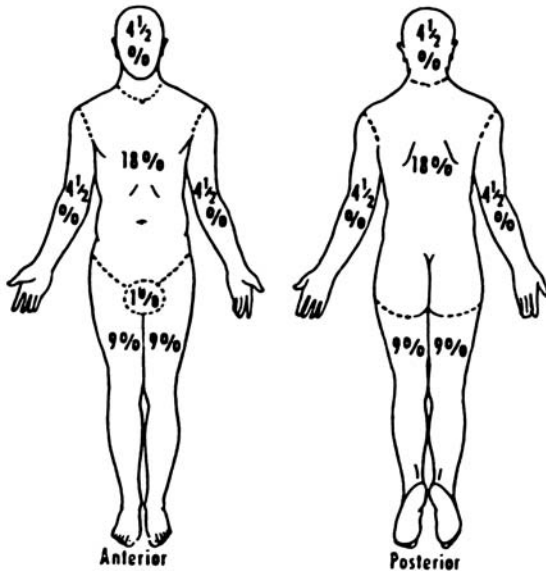
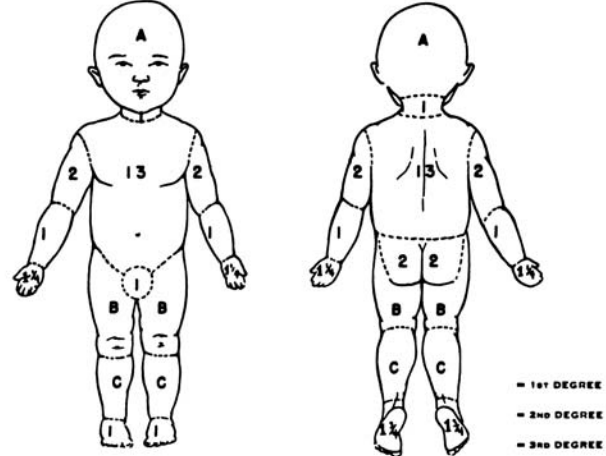


Fig. 8-2

BURN SHEET

NAME _____ AGE _____ NUMBER _____
 BURN RECORD. AGES - BIRTH - 7 1/2 DATE OF OBSERVATION _____



RELATIVE PERCENTAGES OF AREAS AFFECTED BY GROWTH

| AREA | AGE 0 | 1 | 5 |
|--------------------|-------|-------|-------|
| A 1/2 OF HEAD | 9 1/2 | 8 1/2 | 6 1/2 |
| B 1/2 OF ONE THIGH | 2 1/2 | 3 1/2 | 4 |
| C 1/2 OF ONE LEG | 2 1/2 | 2 1/2 | 2 1/2 |

% BURN BY AREAS

PROBABLE } HEAD _____ NECK _____ BODY _____ UP. ARM _____ FOREARM _____ HANDS _____
 3rd° BURN } GENITALS _____ BUTTOCKS _____ THIGHS _____ LEGS _____ FEET _____

TOTAL BURN } HEAD _____ NECK _____ BODY _____ UP. ARM _____ FOREARM _____ HANDS _____
 } GENITALS _____ BUTTOCKS _____ THIGHS _____ LEGS _____ FEET _____

SUM OF ALL AREAS _____ PROBABLY 3rd° _____ TOTAL BURN _____

Fig. 8-3

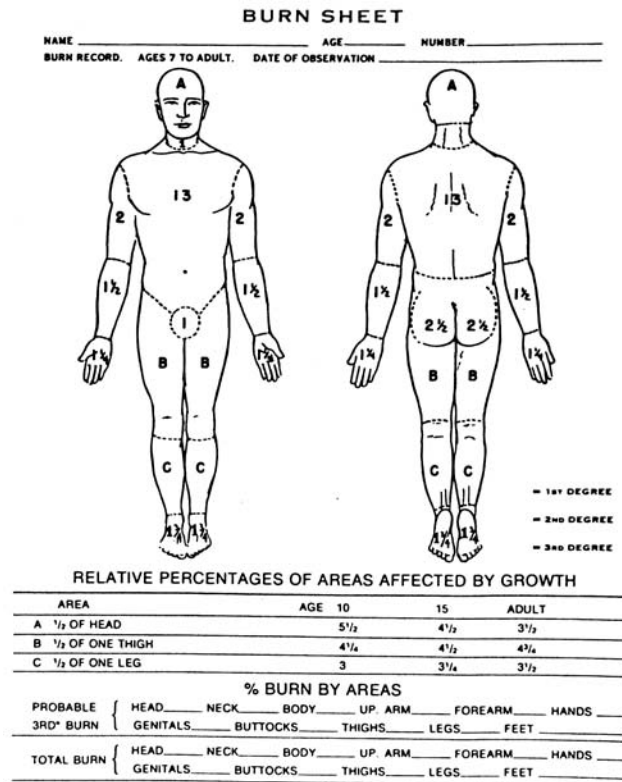


Fig. 8-4

2. Age: burns at the extremes of age carry a greater morbidity and mortality
3. Depth: difficult to assess initially
 - a. History of etiologic agent and time of exposure helpful
 - b. Classification (Fig. 8-5)
 - i. First degree: erythema but no skin breaks
 - ii. Second degree: blisters, red and painful
 - (a) Superficial partial-thickness, involves epidermis and upper dermis
 - (b) Deep partial-thickness, involves deeper dermis
 - iii. Third degree: full-thickness-insensate, charred or leathery
 - iv. Fourth degree: muscle, bone
4. Location: face and neck, hands, feet, and perineum may cause special problems and warrant careful attention; often necessitate hospitalization/burn center
5. Inhalation injury: beware of closed quarters burn, burned nasal hair, carbon particles in pharynx, hoarseness, conjunctivitis
6. Associated injuries, e.g. fractures

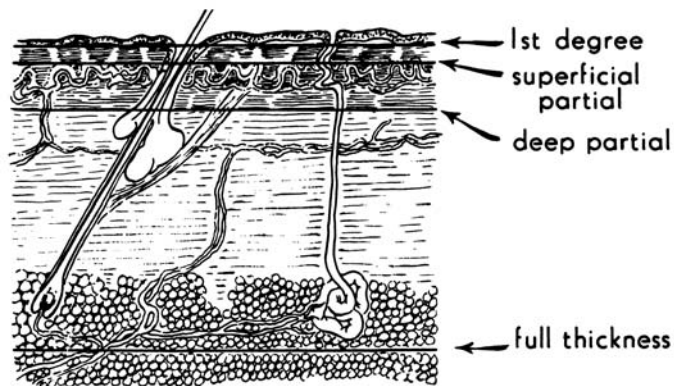


Fig. 8-5

7. Co-morbid factors, e.g. pre-existing cardiovascular, respiratory, renal and metabolic diseases; seizure disorders, alcoholism, drug abuse
8. Prognosis: best determined by burn size (TBSA) and age of patient, inhalation injury
9. Circumferential burns: can restrict blood flow to extremity, respiratory excursion of chest and may require escharotomy

C. Categorization of burns is used to make treatment decisions and to decide if treatment in a burn center is necessary (Table 8-1, Table 8-2)

D. Treatment plan

1. History and physical exam
 2. Relieve respiratory distress — escharotomy and/or intubation
 3. Prevent and/or treat burn shock — IV — large bore needle
 4. Monitor resuscitation — Foley catheter and hourly urine output
 5. Treat ileus and nausea — N.G. tube if > 20% burn
 6. Tetanus prophylaxis
 7. Baseline laboratory studies i.e. Hct., UA, FBS, BUN, chest x-ray, electrolytes, EKG, crossmatch, arterial blood gases, and carboxyhemoglobin
 8. Cleanse, debride, and treat the burn wound
- E. Respiratory distress
1. Three major causes of respiratory distress in the burned patient:
 - a. Unyielding burn eschar encircling chest
 - i. Distress may be apparent immediately
 - ii. Requires escharotomy (cutting into the eschar to relieve constriction)
 - b. Carbon monoxide poisoning
 - i. May be present immediately or later
 - ii. Diagnosed by carboxyhemoglobin levels measured in arterial blood gas
 - iii. Initial Rx is displacement of CO by 100% O₂ by facemask
 - iv. Hyperbaric oxygen treatment may be of value

| Categorization of burns (American Burn Association): | | | |
|---|--|---------------------------------------|--------------------------------|
| | Major Burn | Moderate Burn | Minor Burn |
| Size-Partial thickness | > 25% adults > 20% children | 15-25% adults 10-20% children | < 15% adults < 10% children |
| Size-Full thickness | >10% | 2-10% | < 2% |
| Primary areas | major burn if involved | not involved | not involved |
| Inhalation injury | major burn if present or suspected | not suspected | not suspected |
| Associated injury | major burn if present | not present | not present |
| Co-morbid factors | poor risk patients make burn major | patient relatively good risk | not present |
| Miscellaneous | electrical injuries | | |
| Treatment environment | usually specialized burn care facility | general hospital with designated team | often managed as out-patient |

Table 8-1

| Burns That Dictate Patient Admission to a Hospital or Burn Center |
|--|
| <ul style="list-style-type: none"> • 2° and 3° burns greater than 10% of BSA in patients under 10 or over 50 years of age • 2° and 3° burns greater than 20% BSA in any age group • 2° and 3° burns posing a serious threat of functional or cosmetic impairment, e.g. the face, hands, feet, genitalia, perineum, and about major joints) • 3° burns greater than 5% BSA in any age • Electrical burns including lightning • Chemical burns posing a serious threat of functional or cosmetic impairment • Inhalation injury • Burns associated with major trauma |

Table 8-2

- c. Smoke inhalation leading to pulmonary injury
 - i. Insidious in onset (18-36) hours
 - ii. Due to incomplete products of combustion, not heat
 - iii. Causes chemical injury to alveolar basement membrane and pulmonary edema
 - iv. Initial Rx is humidified O₂ but intubation and respiratory support may be required
 - v. Secondary bacterial infection of the initial chemical injury leads to progressive pulmonary insufficiency
 - vi. Severe inhalation injury alone or in combination with thermal injury carries a grave prognosis
 - vii. Three stages of presentation have been described:
 - (a) Acute pulmonary insufficiency (immediately post burn to 48 hours)
 - (b) Pulmonary edema (48-72 hours)
 - (c) Bronchopneumonia (25 days)

E. Burn shock

1. Massive amounts of fluid, electrolytes, and protein are lost from circulation almost immediately after burning (Table 8-3)

Burn or Associated Condition Dictating Extra Fluid Administration

- Underestimation of the % TBSA burn
- Burn greater than 80% TBSA
- Associated traumatic injury
- Electrical burn
- Associated inhalation injury
- Delayed start of resuscitation
- 4° burn
- Administration of osmotic diuretics
- Pediatric burns

Table 8-3

2. Resuscitation requires replacement of sodium ions and water to restore plasma volume and cardiac output
 - a. Many formulas have been reported to achieve resuscitation
 - i. This can be given by prescribing 4cc Ringer's lactate/Kg/%TBSA burn over the first 24 hours (Baxter or Parkland Hospital formula)
 - ii. 1/2 of the first 24 hour fluid requirement should be given in the first eight hours postburn and the remaining 1/2 over the next 16 hours
 - b. A plasma volume gap may remain restored between 24-30 hours postburn by administering .35-.50cc plasma/Kg/% TBSA burn
 - c. After 30 hours D5W can be given at a rate to maintain a normal serum sodium

G. Monitoring resuscitation

1. Urine output 30-55cc/hr in adults and 1.2cc/Kg/hr in children < age 12
2. A clear sensorium, pulse <120/min, HCO₃ > 18 meq/L, cardiac output >3.1 L/M²
3. CVP in acute major burns is unreliable

H. Treatment of the burn wound (Table 8-4)

1. Wound closure by the patient's own skin is the ultimate goal of treatment
 - a. By spontaneous healing
 - b. Autograft
 - c. Allograft
 - d. Xenograft
 - e. Artificial skin
 - f. Cultured epithelial cells
2. Specific treatment of the burn wound differs from one burn center to another
 - a. The most commonly employed topical antibacterials are silver sulfadiazine (Silvadene®) and mafenide acetate (Sulfamylon®)
 - b. Status of burn wound bacterial colonization and effectiveness of topical antibacterial treatment can be monitored by biopsies of wound for quantitative and qualitative bacteriology

Sample Orders

For a 70 Kg 40 year old patient with a 40% flame burn:

1. Admit to ICU portion of burn center
2. Strict bedrest with head elevated 45°
3. Maintain elevation of burned extremities
4. Vital signs: pulse, BP respiration q 15 min, temperature q 2 h
5. Check circulation of extremities (capillary refill or Doppler) q 30 min
6. 100% O₂ face mask
7. Infuse Ringer's lactate at 700cc for first hour, then reassess
8. Measure urinary output by Foley catheter to closed drainage
9. Notify physician of first hour's urine output (must be 30-50cc: 1.2-1.5cc in pediatric patient)
10. N.P.O.
11. N.G. tube to intermittent low suction
12. Measure pH of gastric content q 2 h — stress ulcer prophylaxis (e.g. Zantac)
13. Morphine sulfate 4 mg intravenously q 2-3 hr prn pain — no intramuscular narcotics (unreliable absorption)
14. Tetanus toxoid 0.5cc IM (if patient previously immunized)
15. Send blood for Hct., glucose, BUN, cross match 2 units, electrolytes
16. Urine for U.A. and culture
17. Chest x-ray
18. EKG
19. Arterial blood gases q 6 h and prn
20. Cleanse wounds with Betadine solution, debride all blisters, map injury on Lund-Browder chart, and photograph wounds
21. Apply silver sulfadiazine to all wounds with sterile gloved hand (use reverse isolation technique when burn wounds are exposed)
22. Dress wounds with burn gauze and surgifix
23. Splint extremities as per physical therapist
24. Change all dressings, cleanse wounds, and reapply topical antibacterial q 8 h or q 12 h
25. Bronchoscopy — If inhalation injury suspected

Table 8-4

3. Necrotic tissues may be removed by any of several techniques:
 - a. Formal excision
 - b. Tangential (layered) debridement
 - c. Enzymatic debridement
 - d. Hydrotherapy — a useful adjunct
 4. Autografts should be applied to priority areas first, such as the hands, face and important joints
 5. Once healed, pressure is usually necessary with elastic supports to minimize hypertrophic scarring
 6. Physical therapy — important adjunct in burn care
- I. Complications: can occur in every physiologic system or secondary to burn injury (Table 8-5)
1. Renal failure
 - a. From hypovolemia
 - b. Beware of nephrotoxic antibiotics in the burn patient

Risk Factors in Burn Wound Infection

- I. Patient Factors
 - A. Extent of burn > 30% of body surface
 - B. Depth of burn: full-thickness vs. partial-thickness
 - C. Age of patient (very young or very old at higher risk)
 - D. Pre-existing disease
 - E. Wound dryness
 - F. Wound temperature
 - G. Secondary impairment of blood flow to wound
 - H. Acidosis
- II. Microbial Factors
 - A. Density >10⁵ organisms per gram of tissue
 - B. Motility
 - C. Metabolic products
 1. Endotoxin
 2. Exotoxins
 3. Permeability factors
 4. Other factors
 - D. Antimicrobial resistance

Table 8-5

2. Gastrointestinal bleeding
 - a. More likely in burns over 40%
 - b. Usually remains subclinical
 - c. Antacids and H₂ blockers
 - d. Increased risk with burn wound sepsis
3. Burn wound sepsis
 - a. Monitored by tissue biopsy — qualitative and quantitative
 - b. Must keep bacterial count < 10⁵ bacteria/gm of tissue
 - c. Clinically suspect sepsis with
 - i. Sudden onset of hyper or hypothermia
 - ii. Unexpected congestive heart failure or pulmonary edema
 - iii. Development of acute respiratory distress syndrome
 - iv. Ileus occurring after 48 hours postburn
 - v. Mental status change
 - vi. Azotemia
 - vii. Thrombocytopenia
 - viii. Hypofibrinogenemia
 - ix. Hyper or hypoglycemia is especially suspect if burn > 40% TBSA
 - x. Blood cultures may be positive but in many cases are not
4. Progressive pulmonary insufficiency
 - a. Can occur after:
 - i. Smoke inhalation
 - ii. Pneumonia
 - iii. Cardiac decompensation
 - iv. Sepsis from any cause
 - b. Produces:
 - i. Hypoxemia
 - ii. Hypocarbica
 - iii. Pulmonary shunting
 - iv. Acidosis
5. Wound contracture and hypertrophic scarring
 - a. Largely preventable
 - b. Since a burn wound will contract until it meets an opposing force, splinting is necessary from the outset

- i. Splints are used to prevent joint contractures, e.g. elbow and knee are kept in extension, and MCP joints of fingers in flexion
- c. Timely wound closure with adequate amounts of skin should largely eliminate these problems
- d. Continued postoperative splinting and elastic pressure supports are of value in the remodeling of collagen with prevention of hypertrophic scars

II. CHEMICAL BURNS

A. Pathophysiology

1. Tissue damage secondary to a chemical depends on:
 - a. Nature of agent
 - b. Concentration of the agent
 - c. Quantity of the agent
 - d. Length of time the agent is in contact with tissue
 - e. Degree of tissue penetration
 - f. Mechanism of action

B. Diagnosis

1. Chemical burns are deeper than initially appear and may progress with time
 - a. Fluid resuscitation needs often underestimated
 - b. Watch for renal/liver/pulmonary damage

C. Treatment

1. Initial treatment is dilution of the chemical with water
2. Special attention to eyes — after copious irrigation with saline, consult ophthalmologist
3. After 12 hours initial dilution, local care of the wound with debridement, topical antibacterials, and eventual wound closure is same as for thermal burn

D. Of particular note are:

1. Gasoline
 - a. Excretion by lung
 - b. May cause large skin burn, if immersed
 - c. Watch for atelectasis, pulmonary infiltrates; surfactant is inhibited
2. Phenol
 - a. Dull, gray color to skin, may turn black
 - b. Urine may appear smoky in color

- c. Spray water on burn surface
 - d. Wipe with polyethylene glycol
 - e. Direct renal toxicity
3. Hydrofluoric acid
- a. Irrigate copiously with water
 - b. Subcutaneous injections of 10% of calcium gluconate
 - c. Monitor EKG patients — may become hypocalcemic
 - d. Pulmonary edema may occur if subjected to fumes
4. White phosphorus
- a. Do not allow to desiccate — may ignite
 - b. Each particle must be removed mechanically
 - c. Copper sulfate (2%) may counteract to make phosphorous more visible (turns black in color)
 - d. Watch for EKG changes (Q - T+ interval and S - T and T wave changes)
 - e. May cause hemoglobinemia and renal failure

III. ELECTRICAL INJURIES

A. Pathophysiology

1. Effects of passage of electric current through the body depend on:
 - a. Type of circuit
 - b. Voltage of circuit
 - c. Resistance offered by body
 - d. Amperage of current flowing through tissue
 - e. Pathway of current through the body
 - f. Duration of contact
2. Tissue resistance to electrical current increases from nerve (least resistant) to vessel to muscle to skin to tendon to fat to bone

B. Diagnosis

1. Types of injury
 - a. Arc injury: localized injury caused by intense heat
 - b. Injury due to current
 - i. Due to heat generated as current flows through tissue
 - (a) Injury more severe in tissue with high resistance (i.e. bone)

(b) Vessels thrombose as current passes rapidly along them

- ii. Effects of current may not be immediately seen

C. Special effects of electrical injury

1. Cardiopulmonary

- a. Anoxia and ventricular fibrillation may cause immediate death
- b. Early and delayed rhythm abnormalities can occur
- c. EKG changes may occur some time after the burn

2. Renal

- a. High risk of renal failure due to hemoglobin and myoglobin deposits in renal tubules
 - i. Requires higher urine flow (75cc/hr in adults)
 - ii. Must alkalinize urine to keep hemoglobin and myoglobin in more soluble state
 - iii. Mannitol may be useful to clear heavy protein load

3. Fractures:

- a. Tetanic muscle contractions may be strong enough to fracture bones, especially spine

4. Spinal cord damage

- a. Can occur secondary to fracture or demyelinating effect of current

5. Abdominal effects

- a. Intraperitoneal damage can occur to G.I. tract secondary to current

6. Vascular effects

- a. Vessel thrombosis progresses with time
- b. Delayed rupture of major vessels can occur

7. Cataract formation — late complication

8. Seizures

D. Treatment

1. CPR if necessary
2. Fluids — usually large amounts
 - a. No formula is accurate because injury is more extensive than can be predicted by skin damage
 - b. Alkalinize with NaHCO_3 , if myoglobinuria or hemoglobinuria present

3. Monitoring
 - a. CVP or pulmonary wedge pressure helpful since total capillary leak does not occur as it does in a thermal burn
 - b. Maintain urine output at 75-100cc/hr until all myoglobin and/or hemoglobin disappears from urine
4. Wound Management
 - a. Topical agent with good penetrating ability is needed [i.e. silver sulfadiazine (Silvadene®) or mafenide acetate (Sulfamylon®)]
 - b. Debride non-viable tissue early and repeat as necessary (every 48 hrs) to prevent sepsis
 - c. Major amputations frequently required
 - d. Technetium-99 stannous pyrophosphate scintigraphy may be useful to evaluate muscle damage
5. Treat associated injuries (e.g. fractures)

- (ii) Daily whirlpool and exercise
- (d) Sympathectomy, anti-coagulants, and early amputation of questionable value in controlled studies
- ii. Usually wait until complete demarcation before proceeding with amputations. Non-viable portions of extremities will often autoamputate with good cosmetic and functional results.

B. Hypothermia

1. Diagnosis
 - a. Core temperature $< 34^{\circ}\text{C}$
 - b. Symptoms and signs mimic many other diseases
 - c. High level of suspicion necessary during cold injury season
2. Treatment
 - a. Must be rapid to prevent death
 - b. Monitor EKG, CVP, and arterial blood gases and pH during warming and resuscitation, maintain urine output of 50cc/hr
 - c. Begin Ringer's Lactate with 1 ampule NaHCO_3
 - d. Oral airway or endotracheal tube if necessary
 - e. Rapidly rewarm in 40° hydrotherapy tank (requires 1-2 hours to maintain body temperature at 37°C)
 - f. Treat arrhythmias with IV Lidocaine drip if necessary
 - g. Evaluate and treat any accompanying disease states

IV. COLD INJURIES

The two conditions of thermal injury due to cold are local injury (frostbite) and systemic injury (hypothermia)

A. Frostbite

1. Pathophysiology
 - a. Formation of ice crystals in tissue fluid
 - i. Usually in areas which lose heat rapidly (e.g. extremities)
 - b. Anything which increases heat loss from the body such as wind velocity, or decreases tissue perfusion, such as tight clothing, predisposes patient to frostbite
 - c. Ability of various tissue to withstand cold injury is inversely proportional to their water content
2. Treatment
 - a. The key to successful treatment is rapid rewarming in a 40°C waterbath
 - i. Admission to hospital usually required
 - (a) Tetanus prophylaxis
 - (b) Wound management
 - (c) Physical therapy
 - (i) Maintenance of range of motion important

V. LIGHTNING INJURIES

- A. Cutaneous effects — lightning strikes may cause cutaneous burn wounds
 1. Contact burns from clothing on fire or contact with hot metal (i.e. zippers, etc)
 2. Entry and exit burns are usually small, may be partial or full thickness
 3. Lightning burns are not the same as electrical burns — don't get deep tissue injury
- B. May have temporary ischemic effects on extremity — pallor or neurologic deficits. Spontaneous recovery after a few hours is the rule — probably due to local

vasoconstriction

- C. Systemic effects can occur such as arrhythmias, cataracts, CNS symptoms

CHAPTER 8 — BIBLIOGRAPHY

THERMAL INJURIES

1. Gibran, N.S. and Heimbach, D.M. Current status of burn wound pathophysiology. *Clin Plast Surg.* 2000; 27:11-22.
2. Matthews, M.S. and Fahey, A.L. Plastic surgical considerations in lightning injuries. *Ann Plast Surg.* 1997; 39:561-5.
3. van Zuijlen, P.P. et al. Dermal substitution in acute burns and reconstructive surgery: a subjective and objective long-term follow-up. *Plast Reconstr Surg.* 2001; 108: 1938-46.

CHAPTER 9

AESTHETIC SURGERY

Aesthetic surgery includes those procedures that provide an enhancement of one's appearance to improve one's self-esteem. The goals of patients should be realistic and their motivation should be appropriate. Unrealistic expectations and/or personality disorders should alert the surgeon to the possibility of refusing to accept the patient or to refer the patient for psychiatric evaluation.

There are many valid reasons for seeking aesthetic surgery. A teenager may desire a more pleasing nose, a young woman may want her breasts enlarged so she is able to wear certain clothing or swimming attire, a balding man may want his hair restored, a public relations person may want to have a more youthful appearance with a facelift, etc. The common denominator of these examples is the reasonable desire to improve one's outward appearance for oneself rather than for another person or reason.

If patients are selected carefully and their expectations are realistic, then well-executed surgical procedures generally will result in a happy patient and a gratified surgeon. The patient's self-image is improved and self-confidence is increased. If patients, on the other hand, are poorly selected, even if the procedure is performed flawlessly, the outcome may be tragic for both the patient and the surgeon. If the deformity is minimal and the concern of the patient is great, the chances for a successful outcome are small and the chance for an untoward result is great. Do not operate on these patients.

Commonly performed aesthetic surgical procedures can be classified in many ways. One way is by anatomic location.

I. FACIAL REJUVENATION

A. Facelift

1. Anatomy

- a. Facial Nerve trunk, rami, branches and their relations to surface landmarks
 - i. Innervation, position of muscle of facial expression
- b. Parotid gland/duct anatomy
- c. SMAS
 - i. SMAS (superficial myoaponeurotic system):

superficial muscle-fascial layer in the head and neck; originating as the platysma in the neck extending superiorly as a thin layer of fascia just below the subcutaneous fat in the face and terminating superior to that as the superficial temporal fascia

- 2.. Operative Options
 - a. Skin Only
 - b. SMAS Plication/Excision Deep plane
 - c. Mini
 3. Post-Operative Issues
 - a. Hematoma
 - b. Facial Nerve Injury
 - c. Scarring
 - d. Alopecia
- B. Upper Blepharoplasty
1. Anatomy
 - a. Anterior Lamella
 - b. Posterior Lamella
 2. Pre-Operative Evaluation
 - a. Ptosis vs. Levator dysfunction
- C. Lower Blepharoplasty
1. Operative Options
 - a. Transconjunctival
 - b. Sub-ciliary/transcutaneous
 - c. Canthopexy/Canthoplasty
 - d. Fat pads (medial, middle and lateral) need to be addressed
 - i. Removal or repositioning
- D. Brow Lift
1. Operative Options
 - a. Endoscopic
 - i. Fixation techniques
 - ii. Cortical Tunnel
 - iii. Endotines®
 - iv. Resorbable Screw fixation
 - b. Hairline incision
 - c. Browline

- E. Neck Lift
 1. Open
 2. Endoscopic
 3. Platysmal plication
 4. Lipectomy (direct or suction)
 5. Repositioning of submandibular glands
- F. Facial Augmentation
 1. Cheek Implants
 2. Fat Transfer

II. Rhinoplasty

- A. Terminology
1. Rostral
 2. Caudal
- B. Anatomy
1. Surface Anatomy
 - a. Supra-tip
 - b. Tip
 - c. Valves (internal and external)
 - d. Vascular supply
 - e. Innervation
 - f. Musculature
- C. Deformities
1. Saddle nose
 2. Septal Deviation (Crooked nose)

III. BREASTS

- A. Augmentation mammoplasty to increase size of breasts
1. Incisions are made to keep scars as inconspicuous as possible, and may be located in the breast crease, around the nipple or in the axilla. Breast tissue and skin is lifted to create a pocket for each implant
 2. The breast implant may be inserted under breast tissue or beneath the chest wall muscle
 3. After surgery, breasts appear fuller and more natural in contour. Scars will fade in time
- B. Mastopexy to reposition ptotic breasts
1. Incisions outline the area of skin to be removed and the new position for the nipple
 2. Skin formerly located above the nipple is brought down and together to reshape the breast

3. Sutures close the incision, giving the breast its new contour and moving the nipple to its new location
4. After surgery, the breasts are higher and firmer, with sutures located around the areola, below it, and sometimes in the crease under the breast

III. SOFT TISSUE FILLERS

- A. Non-permanent
 1. Autologous
 - a. Fat
 - b. Dermafat grafts
 - c. Fascial grafts (i.e., — fascia lata)
 - c. Isolagen
 - i. A suspension cultured autologous fibroblasts harvested by skin biopsy of pt.
 2. Homologous
 - a. Alloderm®
 - i. acellular dermal graft is derived from skin obtained from tissue banks
 - ii. can be micronized
 3. Human collagens
 - a. Cosmoderm®
 - b. Cosmoplast®
 4. Allograft
 - a. Bovine collagens
 - i. Zyderm®
 - ii. Zyplast®
 5. Synthetic
 - a. Radiesse™ (formerly marketed as Radiance™)
 - i. microspheres of calcium hydroxylapatite-based implant
 - ii. stimulate natural collagen growth, actually causing new tissue development
 - iii. is also useful in the treatment of facial lipoatrophy (a stigmatizing effect of HIV), vocal cord deficiencies, oral and maxillofacial defects, as well as scars and chin dimples
 - b. Hyaluronic acid
 - i. Restylane® (Q-med)
 6. Permanent
 - a. Artecoll /Artefil

- i. polymethylmethacrylate spheres suspended in bovine collagen

V. SKIN REJUVENATION

- A. Chemical peels for facial wrinkles
 1. Alphahydroxy acids — lightest peels
 2. Trichloroacetic acid — intermediate in strength
 3. Phenol/croton oil — most efficacious
 4. Chemical peel is especially useful for the fine wrinkles on the cheeks, forehead and around the eyes, and the vertical wrinkles around the mouth
 5. The chemical solution can be applied to the entire face or to a specific area — for example around the mouth — sometimes in conjunction with a facelift
 6. At the end of the peel, various dressings or ointments may be applied to the treated area
 7. A protective crust may be allowed to form over the new skin. When it's removed, the skin underneath will be bright pink
 8. After healing, the skin is lighter in color, tighter, smoother, younger looking
- B. Laser Resurfacing
 1. Laser surfacing is also used to improve facial wrinkles and irregular skin surfaces
 2. In many cases, facial wrinkles form in localized areas, such as near the eyes or around the mouth. The depth of laser during treatment can be tightly controlled so that specific areas are targeted as desired
 3. When healing is complete, the skin has a more youthful appearance
- C. Dermabrasion to improve raised scars or irregular skin surface
 1. In dermabrasion, the surgeon removes the top layers of the skin using an electrically operated instrument with a rough wire brush or diamond impregnated bur

CHAPTER 9 — BIBLIOGRAPHY

AESTHETIC SURGERY

1. American Society of Plastic Surgeons. Statement on Liposuction. June 2000.
2. Clinics in Plastic Surgery. Selected issues. Facial aesthetic surgery. 24:2, 1997. Aesthetic laser surgery. 27:2, 2000. New directions in plastic surgery, part I. 28:4, 2001. New directions in plastic surgery, part II. 29:1, 2002.
3. LaTrenta, G. Atlas of Aesthetic Breast Surgery. New York: Elsevier Science, 2003.
4. Peck, G.C. and G.C., Jr. Techniques in Aesthetic Rhinoplasty. New York: Elsevier Science, 2002.
5. Plastic Surgery Educational Foundation. Patient Education Brochures, by topic. Arlington Heights, IL. 1-800-766-4955.
6. Rees, T.D. and LaTrenta, G.S. Aesthetic Plastic Surgery, 2 vol. New York: Elsevier Science, 1994.
7. Spinelli, H. Atlas of Aesthetic Eyelid Surgery. New York: Elsevier Science, 2003.
8. Coleman SR, Saboeiro AP. Fat grafting to the breast revisited: safety and efficacy. *Plast Reconstr Surg*. 2007 Mar;119(3):775-85; discussion 786-7

CHAPTER 10

BODY CONTOURING

Body contouring may be considered a component of Aesthetic surgery by utilization of techniques and procedures that will clearly improve and enhance one's appearance and potentially one's self-esteem. Additionally, body contouring procedures are also utilized to improve on general health, such as the removal of chronically macerated and infected skin and subcutaneous tissues. There has been a dramatic rise in the number of body contouring patients which correlates well with the increased number of gastric bypass patients. These patients will generally have very dramatic weight loss without the benefit of enough elastic recoil of the skin. Unfortunately, bariatric surgery patients are not simply left with familial fat bulges, but rather display aprons of excess skin. This may lead to hygiene issues under the aprons with tissue maceration, skin breakdown and even chronic or recurrent infections. Two basic methods — liposuction and excisional surgery — are utilized for body contouring.

I. LIPOSUCTION

- A. This is true body contouring and is not utilized for weight loss
- B. Best results obtained when there is localized excess fat
3. Generalized excess fat (mildly or moderately overweight) may still benefit, but may assume potentially less dramatic results and potentially involve more risk
- C. Utilizes suction (vacuum pumps for larger volumes and syringe suction for smaller volume), and cannulas (various aspiration apertures are available)
- D. Surgical techniques:
 1. Cannulas may be moved by the surgeon alone
 2. power-assisted liposuction (electric or pneumatic reciprocating cannulas)
 3. ultrasound-assisted liposuction (cavitation for adipose disruption prior to removal) or
 4. Laser assisted liposuction (energy disruption of the adipose prior to absorption)
- E. Precise and accurate preoperative markings are essential to quality results — mark topographically, estimate volumes to remove, mark areas to avoid
- F. Postoperative support garments often utilized

| Operative technique | Infiltrate | Estimate of Blood Loss (as a % of volume aspirated) |
|---------------------|-------------------------------------|---|
| Dry | No infiltrate | 20-45 |
| Wet | 200-300 cc's/area | 4-30 |
| Superwet | 1 cc / 1 cc aspirate | 1 |
| Tumescent | 2-3 cc infiltrate per 1 cc aspirate | 1 |

Table 10-1

II. EXCISIONAL BODY CONTOURING SURGERY

Designed to treat skin quality problems including laxity, pannus formations and cellulite

A. Breast

1. May involve breast reduction or mastopexy (breast lift procedure)
2. Significant excess skin may require continuation of the scar onto the lateral chest wall or onto the back to remove the “dog ears”
3. Repositions the nipple at the inframammary fold and re-supports ptotic breast tissue

B. Arms

1. Indicated for moderate to severe skin laxity of the arms with or without associated arm fat deposits
2. Mild skin laxity with fat deposits — consider liposuction instead of excision
3. Mark with arms abducted 90 degrees
4. Mark generous vertical (axillary) ellipse
5. Longitudinal (arm) incision line marked approximately 4 cm above and parallel to the medial bicipital sulcus toward medial epicondyle
6. Inferior excision line estimated by pinching, but final determination done in the operating room
7. Axillary fascial anchoring sutures utilized to gain long term support

C. Abdomen

Panniculectomy vs. Abdominoplasty

1. Panniculectomy — excision of excess apron of tissue alone

- a. Usually performed to improve hygiene issues
 - b. Tissue under pannus frequently macerated, ulcerated or infected
2. Abdominoplasty — excision of excess abdominal skin and fat, and usually involves plication of the fascia for abdominal wall tightening/contouring
 3. Abdominoplasty — Anterior vs. Circumferential
 4. Anterior Abdominoplasty
 - a. Removal of tissue frequently from the umbilicus to the pubis
 - b. Tissue undermined up to costal margin
 - c. Abdominal wall fascia usually plicated for abdominal wall tightening /contouring
 - d. Patient marked standing
 - e. Umbilicus is preserved on its stalk and delivered through the flap after caudal mobilization of the flap
 - f. Closure involves the superficial fascial system and skin
 - g. Achieves excess tissue removal, abdominal and waist contouring
 5. Circumferential Abdominoplasty — Abdominoplasty with transverse flank, thigh and buttock lift — lower body lift (abdominoplasty, transverse flank, thigh and buttock lift and possibly medial thigh lift)
 - a. Benefits patients with abdominal as well as flank and posterior trunk skin excess and laxity
 - b. Abdominal tissue undermined and plicated as noted under Abdominoplasty
 - c. Excess lateral and posterior skin measured and marked preoperatively by pinch testing – final excision volume determined intraoperatively similar to brachioplasty
 - d. Lateral and posterior skin-subcutaneous flaps are dissected in cephalic and caudal directions
 - e. No direct or discontinuous undermining is performed over the buttocks
 - f. Direct undermining of the skin-subcutaneous flaps done anteriorly only through the superficial fascial system zones of adherence

- g. Discontinuous cannula undermining is performed distally if aesthetic deformity extends into lower half of the thighs
- D. Medial thigh lift
 - 1. Classic medial thigh lift plagued with problems such as inferior migration and widening of the scars, lateral traction deformities of the vulva, and early ptosis recurrence
 - 2. Results improved with suspension of the superficial fascial system to Colles fascia along the pubic ramus
- E. Back
 - 1. Direct excision of back rolls can be achieved
 - 2. Incisions and excisions are separate from buttock procedures
 - 3. Excisions may be combined with breast procedures
- F. Buttock
 - 1. Excision may be superior or inferior aspect of the buttock
 - 2. Inferior tissue excision may lead to flattening of the buttock and an inferior buttock scar as opposed to crease
 - 3. Excision may be combined with the lower body lift

CHAPTER 10 — BIBLIOGRAPHY

BODY CONTOURING

1. Achauer, BM, Eriksson, E, Guyuron, B, Coleman III, JJ, Russell, RC, and Vander Kolk, CA, Plastic Surgery Indications, Operations, and Outcomes, 5 vol. Mosby, 2000
2. Aston, SJ, Beasley, RW, and Thorne, CNM, Grabb and Smith's Plastic Surgery, Vol. 5, Lippincott-Raven, 1997
3. McCarthy, JG, Galiano, RD, Boutros SG, Current Therapy in Plastic Surgery, Saunders, Elsevier, 2006
4. Shestak, KG (editor) Abdominoplasty, Clinics in Plastic Surgery, 31 (4) October 2004

NOTES